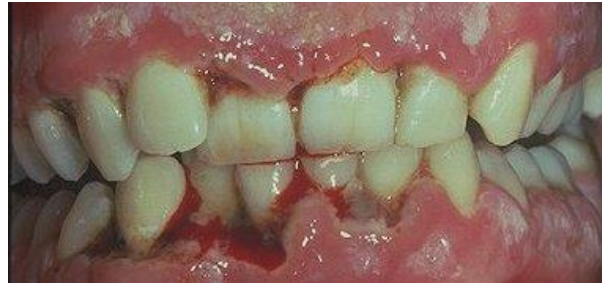



NECROTIZING ULCERATIVE PERIODONTITIS

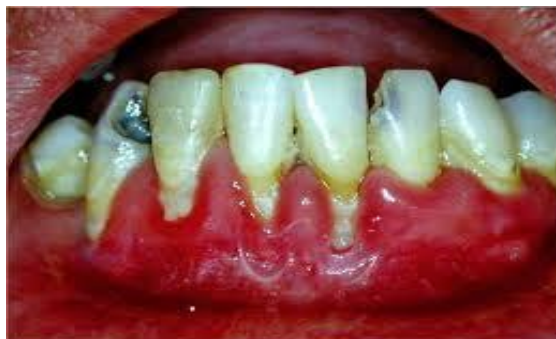

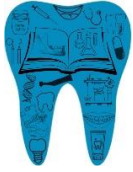Necrotizing ulcerative periodontitis (NUP) is characterized by soft tissue necrosis, rapid periodontal destruction, and interproximal bone loss. Unlike other periodontal diseases, it presents substantial necrosis of gingival tissues, and loss of periodontal ligament and alveolar bone.

AIDS Associated Ulcerative Periodontitis :

Clinical Features :

- ❖ Large areas of soft tissue necrosis with exposure of bone
- ❖ Sequestration of bone
- ❖ Lesions may extend upto the buccal vestibule / palate & turn into **Necrotizing Stomatitis**

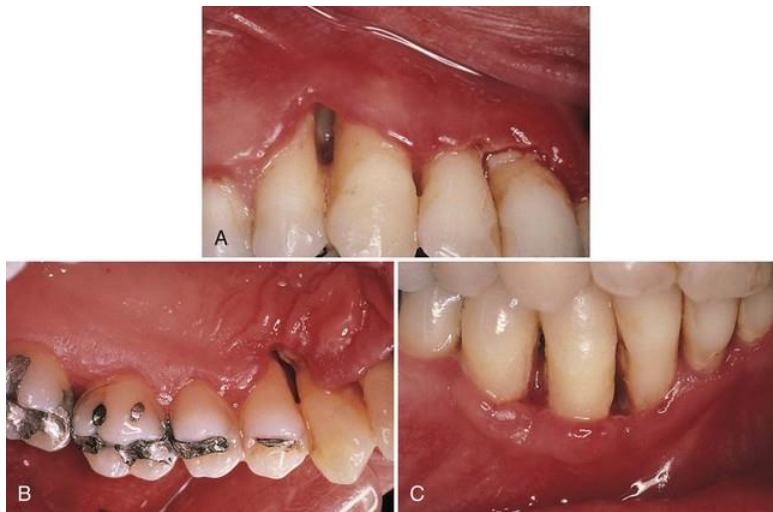



Non-AIDS Type Ulcerative Periodontitis :

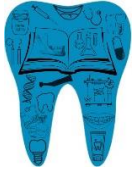Clinical Features :

- ❖ Ulceration & Necrosis of gingival margins covered by pseudomembranous slough
- ❖ The ulcerated margins are surrounded by an erythematous halo
- ❖ Lesions are very painful
- ❖ Profuse bleeding is seen
- ❖ Localized lymphadenopathy
- ❖ Fever , Malaise
- ❖ Deep interdental Osseous craters

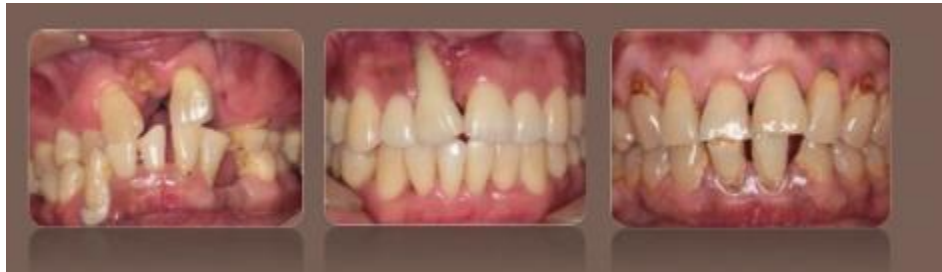

Treatment :

- ✓ Local debridement of the lesions
- ✓ Good oral hygiene instructions
- ✓ Irrigation
- ✓ Application of topical antimicrobials & systemic antibiotics
- ✓ Analgesics to relieve pain



REFRACTORY PERIODONTITIS



It is defined as “Those cases which do not respond to any treatment provided whatever the thoroughness or frequency”.

Etiology :

- ✚ Abnormal host response
- ✚ Resistance from pathogenic periodontal microflora
- ✚ Furcation involvement
- ✚ Irregular root surfaces
- ✚ Plaque retentive factors like palatogingival groove
- ✚ Smoking
- ✚ Systemic diseases
- ✚ Specific bacteria like : Bacteroides forsythus , Fusobacterium & Campylobacter, Staphylococcus intermedius , P.gingivalis

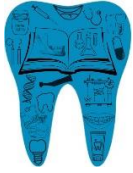Clinical Features :

- New areas of attachment loss
- Progressive loss of attachment
- Persistent bleeding on probing
- Repeated failure of periodontal treatment

Treatment :

- ✓ Mechanical debridement with antimicrobial therapy

- ✓ Intracanal irrigation with 10% povidine iodine
- ✓ Local drug delivery systems can be reinforced



- ✓ NSAIDs & SDD (Sub antimicrobial/Low dose Doxycycline)
- ✓ Flurbiprofen , naproxen or indomethacin may reduce the production of inflammatory mediators

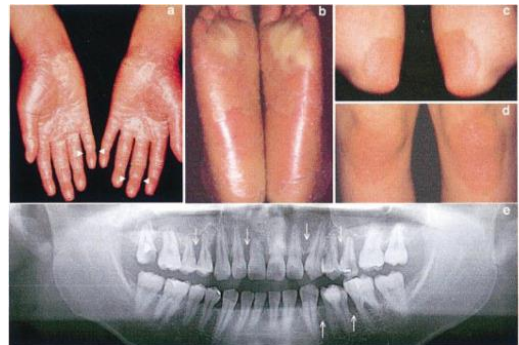
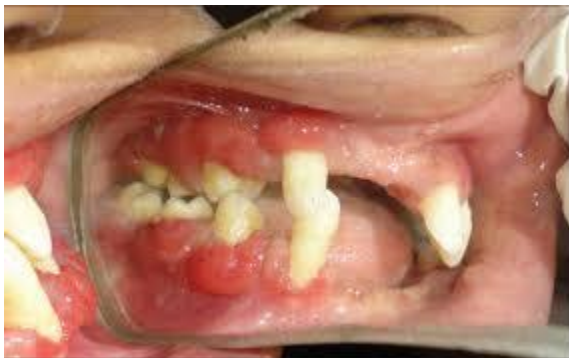PERIODONTITIS IN SYSTEMIC CONDITIONS

1. PAPILLON-LEFEVRE SYNDROME

Papillon-Lefèvre syndrome (PLS) is a rare autosomal recessive disorder, characterized by diffuse palmoplantar keratoderma and precocious aggressive periodontitis, leading to premature loss of deciduous and permanent dentition at a very young age.

C/F :

- ✓ Hyperkeratotic skin lesions & severe destruction of the periodontium
- ✓ Appears before the age of 4 years
- ✓ Skin lesions – Palm , soles , knees & elbows which are hyperkeratotic
- ✓ Premature loss of deciduous & permanent dentition at a young age



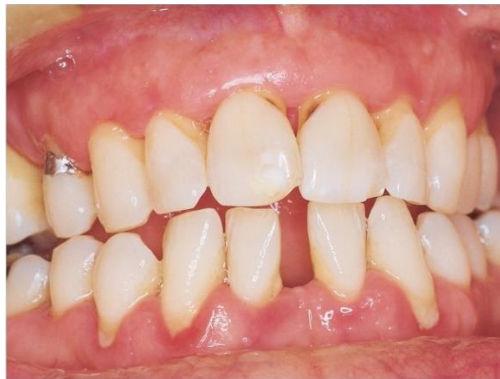2. CHEDIAK-HIGASHI SYNDROME :



Chediak-Higashi syndrome (CHS) is a rare, inherited, complex, immune disorder that usually occurs in childhood characterized by reduced pigment in the skin and eyes (oculocutaneous albinism), immune deficiency with an increased susceptibility to infections, and a tendency to bruise and bleed easily.

C/F :

- ✓ Photophobia
- ✓ Recurrent respiratory tract & sinus infections
- ✓ Neurological & Gastrointestinal disturbances



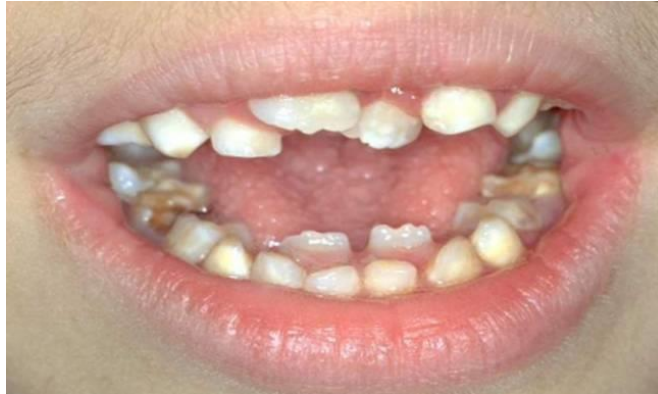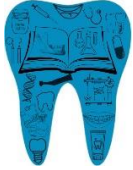3. DOWN SYNDROME (MONGOLISM / TRISOMY 21):

Down's syndrome, also known as trisomy 21, is a genetic disorder caused by the presence of all or part of a third copy of chromosome 21. It is usually associated with physical growth delays, mild to moderate intellectual disability, and characteristic facial features.

C/F :

- ✓ Formation of deep periodontal pockets
- ✓ Marked recession
- ✓ Acute necrotizing lesions
- ✓ High frenal attachment

- ✓ Moderate gingivitis
- ✓ Crowding of teeth
- ✓ Midline diastema
- ✓ Malocclusion may be severe



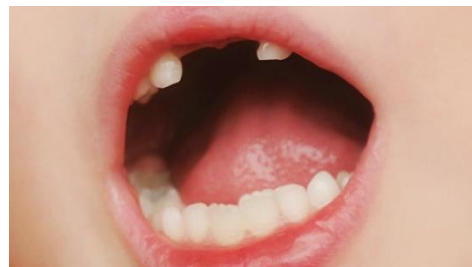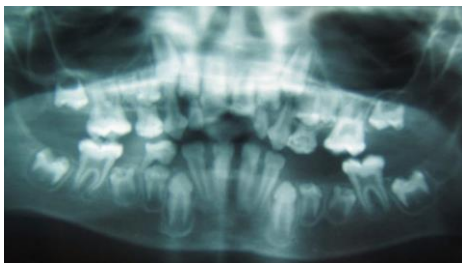
4. HYPOPHOSPHATASIA :

Hypophosphatasia (HPP) is a rare genetic disorder characterized by the abnormal development of bones and teeth. These abnormalities occur due to defective mineralization, the process by which bones and teeth take up minerals such as calcium and phosphorus.

C/F:

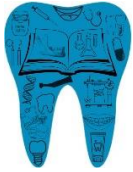- ✓ Rickets
- ✓ Premature loss of teeth
- ✓ Poor Cranial formation

It is of 2 types : Juvenile & Adult type



5. NEUTROPENIA :

- ✓ Circulating neutrophils are reduced in number
- ✓ Destructive generalized periodontal lesions
- ✓ It is of 2 types : **Inherent & Acquired**



6. LEUKOCYTE ADHESION DEFICIENCY :

- ✓ **Leukocyte adhesion deficiency (LAD)**, is a rare autosomal recessive disorder characterized by immunodeficiency resulting in recurrent infections. LAD is currently divided into three subtypes: LAD1, LAD2, and the recently described LAD3, also known as LAD-1/variant.
- ✓ **Acute inflammation of the gingiva is seen**
- ✓ **Rapid Bone loss**
- ✓ **Frequent respiratory tract infections**
- ✓ **Otitis Media**
- ✓ **Proliferation of gingival tissues**

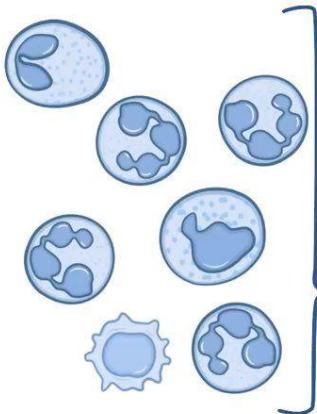
LEUKOCYTE ADHESION DEFICIENCY

↳ RARE INHERITED IMMUNODEFICIENCY

* IMMUNE CELLS FAIL to BIND
to BLOOD VESSEL WALL



* CANNOT REACH SITE of
INFLAMMATION / TISSUE INJURY



PHAGOCYTES

