



## DEVELOPMENTAL DISTURBANCES OF ORAL AND PARAORAL STRUCTURES

- Malformation or defects resulting from disturbance of growth & development are known as developmental anomalies .
- Manifestation of defects is evident either at birth or some times after birth.

### *Developmental disturbances of jaws:*

#### ***I. Anathia:***

- Is a lethal anomaly characterized by hypoplasia or absence of mandible & abnormally positioned ears.
- Autosomal Recessive mode of inheritance.
- More commonly, only a portion of one jaw is missing.
- In maxilla - maybe one maxillary process or even the premaxilla.
- Partial absence of the mandible is even more common. The entire mandible on one side may be missing / frequently only the condyle / the entire ramus.
- Also reported - bilateral agenesis of the condyles and rami .

#### **Pathogenesis:**

- Failure of migration of neural crest mesenchyme into the maxillary prominence at the fourth to fifth week of gestation.
- The prognosis of this condition is very poor and considered to be lethal.

#### ***II. Micrognathia:***

- It refers to small jaw
- Either the maxilla or mandible may be affected

#### **True Micrognathia –**

- 1. Congenital**
- 2. Acquired**

#### **1. Congenital type –**

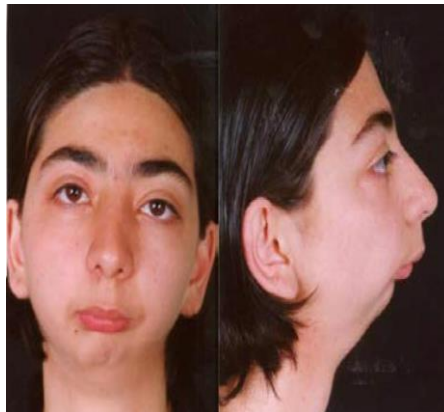- Unknown etiology.



- Associated with other congenital abnormalities like congenital heart disease and the pierre robin syndrome.

## 2. Acquired type:

- Results from disturbance in the area of the temporomandibular joint .
- Eg:ankylosis of the joint caused by trauma or by infection of the mastoid,middle ear or joint itself.
- **Clinical features** : severe retrusion of the chin,steep mandibular angle and deficient chin button.



- **Maxillary Micrognathia:**

- Frequently occur due to a deficiency in the premaxillary area .
- Middle third of the face retracted.
- Suggested cause mouth-breathing

- **Mandibular micrognathia:**

- Severe retrusion of chin and steep mandibular angle

### **III. Macrogathia:**

- It refers to large jaw

- **Macrogathia is associated with:**

1. Pagets disease (Skull & Maxilla)
2. Acromegaly (Mandible)
3. Pituitary gigantism (Whole body)
4. Leontiasis ossea (Maxilla)

- **Madibular prognathism-**

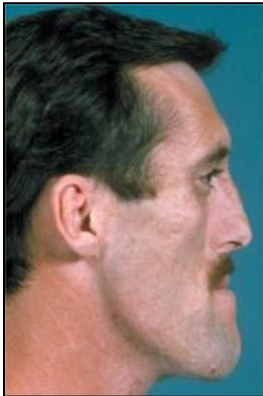- ✓ unknown eitiology, some cases follow hereditary patterns.



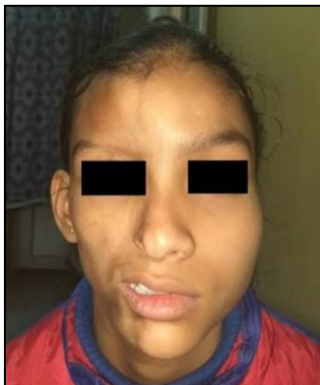- ✓ In many instances prognathism is due to disparity in the size of the maxilla in relation to mandible
- ✓ In other cases mandible is measurably larger .

**Conditions which favor mandibular prognathism are:**

1. Increased height of the ramus
2. Increased mandibular body length
3. Decreased maxillary length
4. Prominent chin button
5. Posterior positioning of the maxilla in relation to the cranium



**IV. Facial hemihypertrophy (hyperplasia):**



- Is a rare developmental anomaly characterized by asymmetric overgrowth of one or more body parts.
- It actually represents a hyperplasia of the tissue rather than hypertrophy

**Hoyme et al Anatomical classification:**

- Complex hemihyperplasia : involvement of half of the body.
- Simple hemihyperplasia : involvement of a single limb .



- Hemifacial hyperplasia: involvement of one side of the face.

### **Etiology:**

- Unknown
- Vascular or lymphatic abnormalities, CNS disturbances, Chromosomal abnormalities.
- Clinical Features: F>M
- Enlargement confined to one side of the body, Unilateral macroglossia, Premature development and eruption.
- Increased size of dentition.

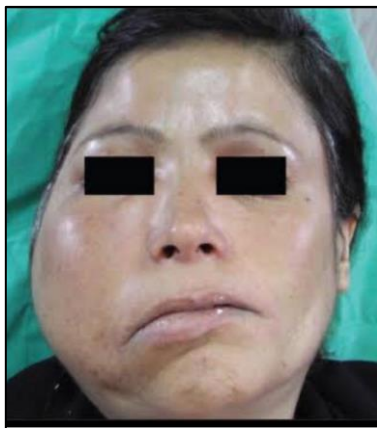### **Syndromes associated:**

1. Neurofibromatosis
2. Proteus syndrome
3. McCune-Albright syndrome
4. Epidermal nevus syndrome

### **Treatment :**

- cosmetic surgery after cessation of growth
- Periodic abdominal ultrasound/MRI to rule out tumors

## V. **Facial hemiatrophy (Parry Romberg syndrome):**



- Slowly progressive atrophy of the soft tissues on one half of the face.
- Characterized by Progressive wasting of subcutaneous fat, accompanied by atrophy of skin, cartilage, bone, muscle
- Occasionally spread to neck and one side of the body
- Rare condition
- Form of localised scleroderma
- Contra lateral Jacksonian epilepsy, trigeminal neuralgia, changes in eyes and hair.



### **Etiology:**

- Cerebral / Vascular disturbance
- Local trauma
- Infection
- Genetic factors

### **Clinical features:**

- 1<sup>st</sup> decade, last for about 3 years before it becomes quiescent, along one branch of trigeminal nerve.
- F> M = 3:2, Slight predilection on left side.
- **Wasting:** Skin, subcutaneous tissue, fat, muscle, cartilage, soft palate, tongue, salivary gland, ears, larynx, kidney.... Pigmented lesions, Vitiligo, Pigmented Nevi, Ocular complications
- **Coup de Sabre**-Painless cleft in Midline of the face or forehead, Bluish hue of skin
- Neurological disorders: 15%
- Ocular: 10-40%
- **O/M:** Incomplete root formation, Delayed eruption, Severe facial asymmetry – facial deformation and difficulty with mastication, Hemiatrophy of tongue and lips, Microdontia.

### **Differential diagnosis:**

- Post traumatic fat atrophy
- Hemifacial microsomia

### **Treatment:**

- No specific treatment.
- Disease is progressive for a period and then remain unchanged

## **ABNORMALITIES OF DENTAL ARCH RELATIONS**

**Class 1:** Straight profile (69%): Normal MD relations of arches

**Class 2:** Convex profile: Mandibular arch distal to maxillary arch

**Div 1:** Bilateral distal, protruding max incisors

**Subdivision:** Unilateral distal, protruding max incisors

**Div 1:** Bilateral distal, retruding max incisors

**Subdivision:** Unilateral distal, retruding max incisors

**Class 3:** Concave profile, Mandibular arch mesial to maxillary arch

**Div 1:** Bilaterally mesial

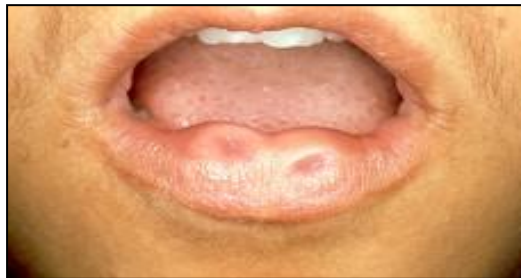**Subdivision:** Unilaterally mesial



## **DEVELOPMENTAL DISTURBANCES OF LIPS AND PALATE:**

### **Congenital lip and commissural pits and fistulas:**

- Malformation of lip
- Hereditary pattern usually
- May occur alone or in association with other developmental anomalies like oral clefts
- Syndrome associated- Van der Woude Syndrome



#### **Etiology:**

Notching of the lips at an early stage of development, with fixation of the tissue at the base of the notch /Failure of complete union of the embryonic lateral sulci of the lip/Commissural pits occur at the site of horizontal facial clefts and may represent defective development of the embryonic fissure.

#### **C/F:**

- Lip pit or fistula: Unilateral/bilateral depression, more common on the lower lip
- Lips sometimes appear swollen
- Commissural pits appear at the corner of the mouth on vermilion surface, preauricular pits may be seen
- Sparse mucous secretions may exude from the base of the pit

**Treatment:** Surgical excision

### **Van der Woude Syndrome (cleft lip syndrome, dimpled papillae of the lip)**

- Autosomal dominant syndrome.
- **Hall mark :** Cleft lip/ Palate & Lower lip pits



- **Etiology:**
  - ✓ Abnormalities in chromosome nos 1q32 & 17p11
  - ✓ Abnormal fusion of lips and palate at 30-50 days post natally
  
- **Clinical features:**
  - ✓ Both genders equally affected.
  - ✓ Hypernasal voice and cleft or bifid uvula.
  - ✓ Lower lip pits.(usually medial to vermilian portion).
  
- **Oral:**
  - ✓ Max Hypodontia
  - ✓ Syngnathia
  - ✓ Ankyloglossia
  
- **Extra-Oral:**
  - ✓ Limb & brain anomalies,
  - ✓ Popliteal webs,
  - ✓ acc nipples,
  - ✓ Cong heart defects
  
- **Treatment:**
  - ✓ Thorough orofacial examination and general physical examination
  - ✓ Surgical repair of cleft lip and cleft palate.

### **Cleft lip and cleft palate**

- Congenital malformations
- Two types of malformations :
  - Cleft lip with or without cleft palate (CL/P)
  - Cleft palate (CP)
- Embryogenesis of lip & palate: 4<sup>th</sup> -12<sup>th</sup> week of gestation, failure of fusion of different processes leads to clefts.
  
- **Pathogenesis:**
  - ✓ Multifactorial threshold hypothesis
  - ✓ Polygenic inheritance explains transmission of isolated cleft lip and cleft palate
  - ✓ Disruption of normal pattern of facial growth or deficiencies of any facial processes
  
- **Predisposing factors:**



- ✓ Hereditary/Environmental factors/Genetic causes [Monogenic inheritance – Single mutant gene (high risk) or polygenic inheritance - Number of genes (low risk)], Nutritional disturbances (insufficient evidence)/Stress: Increase cortisone –
- ✓ Physiological, Emotional, Traumatic
- ✓ Other factors:
  - ✚ Defective vascular supply to involved area, Mechanical disturbance (macroglossia) preventing fusion of parts, Circulating substances like drugs, toxins, alcohol, Infections, Lack of inherent developmental force
- $CL \pm CP > M$ ; Isolated  $CP > F$
- Clefts divided into :-
  - ✓ Syndromic: individuals with additional birth defects.
  - ✓ Non Syndromic: affected individuals with no physical or developmental anomalies.
- Cleft lip can be:
  - ✓ Unilateral
  - ✓ Bilateral
  - ✓ Cleft lip associated with alveolus, primary & secondary palate, soft palate

### **Presenting Features:**

- Difficulty - eating & drinking because of nasal regurgitation of food and drinks.
- Difficulty in speech, Mental trauma, Retrusion of maxilla with narrow upper arch resulting in the upper canines and premolars of affected side to be in lingual occlusion with mandibular teeth, Upper anteriors may be malplaced/deformed or impacted, Repeated ear infections.

### **Classification:**

- Davis and Richie classification
- Veau classification
- Kernahan and Stark symbolic classification
- International Confederation Of Plastic & Reconstructive Surgery Classification

### **Clinical Considerations:**

- Surgically repaired with excellent cosmetic and functional results
- Customary to operate before patient is 1 month old or when he has regained his original birth weight.
- Eating and drinking difficult
- Speech problem serious and tends to increase mental trauma suffered by patient.

### **Treatment:**





- Cleft lip repair should be accomplished during early infancy when child is stable:

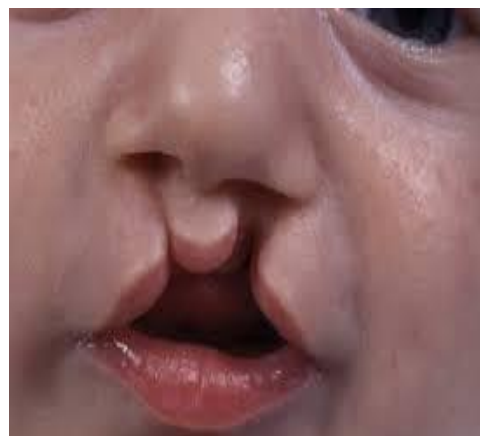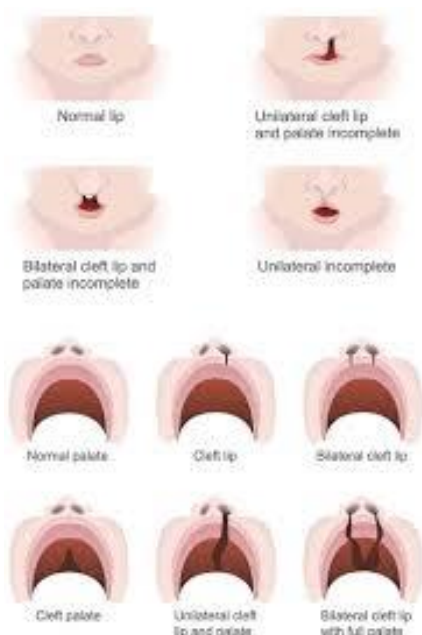**Rule of 3 tens:**

- ✓ 10 weeks old,
- ✓ 10lb weight,
- ✓ Hb level of 10 mg/dl

- In later life, **cheiloplasty** is required.
- Orthodontic treatment recommended and surgically placed orthopedic devices used in infants.
- Closure of cleft palate defects with sliding and pharyngeal flaps by 1 yr of age to promote normal speech. Palatal obturators for patient having difficulty in feeding, eating or drinking.
- Early audiologic and speech evaluation.
- Preventive dental services provided to the patient.
- Plastic surgery procedure to correct aesthetics, function of vermilion border, lip, nose anticipated.
- For child's psychology and development, psychiatric consulted.

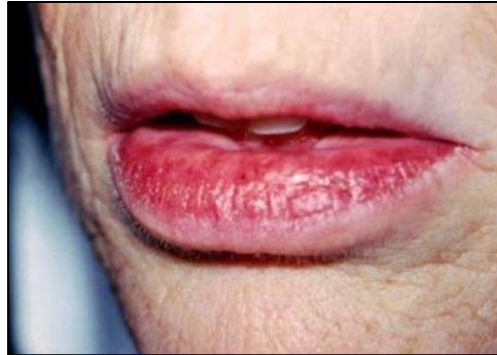**Syndromes associated with cleft palate and lip :**

1. Pierre Robin syndrome
2. Apert's syndrome
3. Marfan syndrome
4. Down's syndrome
5. Stickler syndrome
6. Crouzon syndrome
7. Treacher Collin's syndrome





## **Cheilitis glandularis**



- Deeply suppurative, chronic inflammatory condition of lower lip characterized by mucopurulent exudates from ductal orifices of labial minor salivary gland.
- Progressive enlargement & eversion of lower labial mucosa.
- Results in obliteration of mucosal-vermilion interface
- Labial mucosal membrane is secondarily altered by environmental influences, leading to erosion, ulcerations and crusting.
- Actinic cheilitis .
- Squamous cell carcinoma.

### **Etiology:**

- Chronic irritation
- Unusual repeated manipulation including self inflicted biting or other factitial trauma
- Excessive wetting from compulsive licking
- Lip enlargement due to inflammation, hyperemia, edema, and fibrosis
- Surface keratosis & erosion due to long standing actinic exposure

### **C/F:**

- Lip swelling
- Burning discomfort or a sensation of rawness
- Dysplastic surface epithelial change
- Especially in fair skinned individuals with skin damaged skin



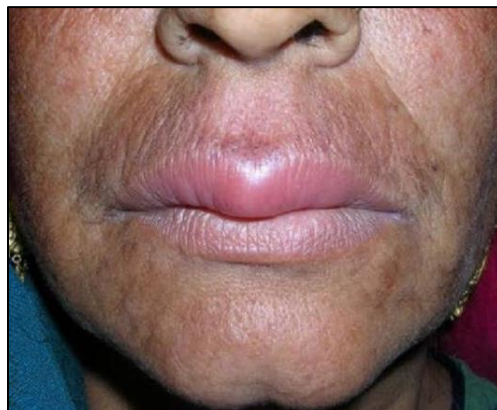## **Classification:**

- Simple type :
  - ✓ Multiple, painless, papular surface lesions with central depressions and dilated canals.
- Superficial (suppurative) type : (baelz disease)
  - ✓ Painless, indurated swelling of lips with shallow ulceration and crusting.
- Deep Suppurative type : (CG apostematosa,CG suppurative profunda, myxadenitis labialis)
  - ✓ Deep seated infection with abscess formation, sinus tracts and fistulas.

## **H/F:**

- Atrophy, distention of acini, ductal ectasia with or without squamous metaplasia, chronic inflammatory infiltration and replacement of glandular parenchyma, and interstitial fibrosis.
- Sinus tracts and suppuration.
- Bacterial infection.
- Others include stromal edema, hyperemia, surface hyperkeratosis, erosion, ulceration.

## **Chelitis granulomatosa**



- Also called as Miescher-Melkersson-Rosenthal syndrome.



- Chronic swelling of the lip due to granulomatous inflammation.

### **Etiology:**

- ✓ Genetic predisposition,
- ✓ Crohn disease,
- ✓ Sarcoidosis,
- ✓ Orofacial granulomatosa,
- ✓ Dietary habits,
- ✓ Contact antigens

### **Clinical Features:**

- Non tender nodular swelling and enlargement of one or both lips
- Accompanied by fever and mild constitutional symptoms like visual disturbances, headache
- Enlarged lip appears cracked and fissured with reddish brown discoloration and scaling
- Fissured lips painful and acquire firm rubbery consistency
- Fissured tongue, loss of taste sensation, decreased salivary gland secretion.
- Facial palsy may precede attacks of edema
- Other cranial nerves (olfactory,auditory,hypoglossal) also affected,
- Psychiatric and neurologic disturbances
- normal lip architecture altered

### **H/F:**

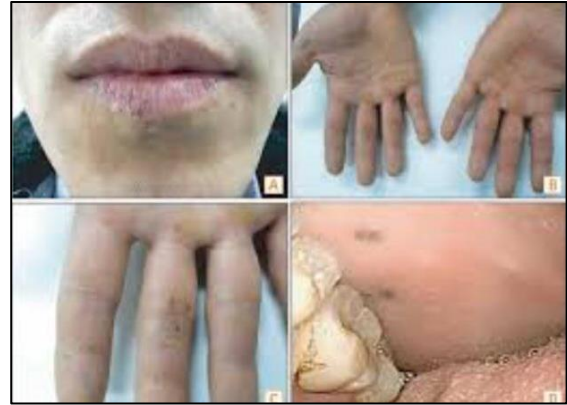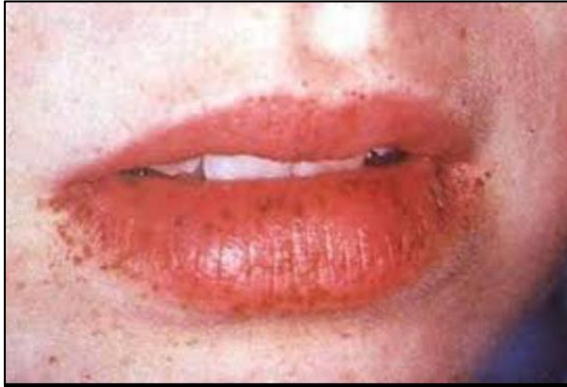- Chronic inflammatory cell infiltration,
- Aggregation of lymphocytes, plasma cells, histocytes,
- Focal noncaseating granuloma formation with epithelioid cells
- Langhans giant cells.

### **Treatment:**

- Patch test to exclude reactions to metals, food additives, or other oral antigens.
- Intralesional corticosteroids, non steroidal anti-inflammatory agents, mast cell stabilizers, clofazimine, tetracycline.
- Surgery and radiations.



## **HEREDITARY INTESTINAL POLYPOSIS SYNDROME**



- Also known as **Peutz-Jeghers syndrome**.
- AD inherited disorder
- Characterised by intestinal hamartomatous polyps (small intestine) in association with mucocutaneous melanocytic macules.

### **Etiology:**

- Germline mutation of the STK11 (serine threonine kinase 11) gene, located on band 19p13.3

### **C/F:**

- Familial history of the syndrome.
- Repeated bouts of abdominal pain, unexplained intestinal bleeding, menstrual irregularities in females.
- Cutaneous pigmentation of perioral areas, fingers, toes.
- Others-precocious puberty, prolapse of tissue from mass, rectal polyp, gynecomastia

### **H/F:**

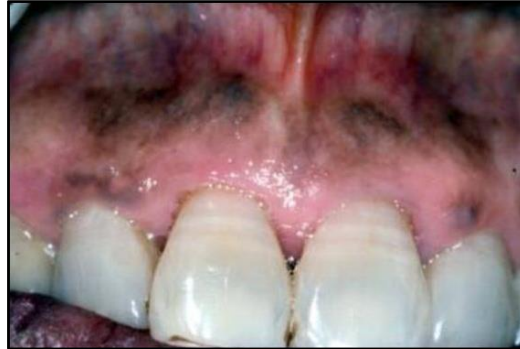Extensive smooth muscle arborization throughout the polyp and psuedoinvasion appearance.

### **Treatment:**

- Surgical treatment.



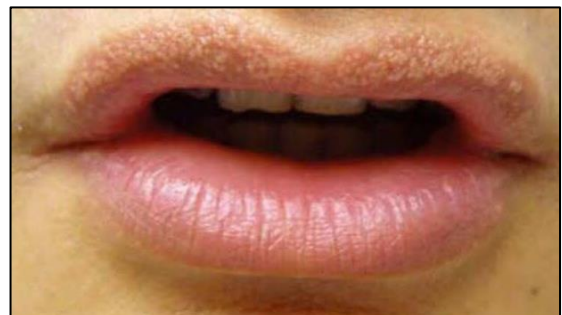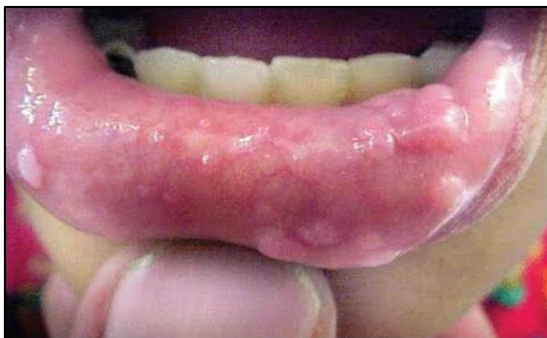## LABIAL AND ORAL MELANOCYTTIC MACULE



- Usually pigmented.
- Focal area of melanin deposition due to local chronic conditions - mechanical trauma, tobacco, smoking, racial background, systemic medication(chloroquine)
- Gender: Female predilection
- Site: vermilion border of lower lip, buccal mucosa, gingiva, palate.
- Well demarcated, uniformly tan to dark brown, asymptomatic, round to ovoid.
- **SMOKER'S MELANOSIS**: found on gingival or buccal mucosa, associated with superficial white/grey keratosis
- Normal st sq epi with abundant melanin deposits within keratinocytes of the basal and parabasal layers.
- Deposits seen within subepithelial stroma, within macrophages/ melanophages.
- No underlying inflammatory response.

## Developmental disturbances of oral mucosa

### Fordyce granules :



- Heterotrophic collection of sebaceous glands in oral mucosa



- **C/P:**
  - ✓ Small, yellow plaques on the mucosa
  - ✓ Bilaterally symmetrical, cheeks
  - ✓ Other sites: Retromolar region, mucosa of lips
  - ✓ Rare – tongue, gingiva, palate & frenum
  
- **C/F:**
  - ✓ Normal sebaceous glands without hair follicles
  - ✓ Focal Epithelial Hyperplasia( Heck`s Disease)
  - ✓ HPV induced epithelial proliferation (HPV-13 & 32)
  - ✓ Contagious
  - ✓ Young / Middle aged
  - ✓ Labial, lingual, buccal mucosa
  - ✓ Lesions: Papillary/smooth flat top, papules, plaques, cobble stone or fissured appearance
  - ✓ Mucosa 8-10 times thicker (Acanthosis & hyperplasia of spinous layer)
  
- **H/F:**
  - ✓ Thick epithelium, extends upwards, hence rete ridge in level with adjacent normal epithelium
  - ✓ Acanthosis
  - ✓ Koilocytic changes of superficial keratinocytes
  - ✓ Mitosoid cell, cell with collapsed nucleus resembling a mitotic figure

**Treatment:**

- ✓ Conservative surgical excision
- ✓ Maybe an oral manifestation of AIDS

**Developmental Disturbances of Gingiva**

***Fibromatosis Gingivae***

- Diffuse fibrous overgrowth of gingival tissues
- Majority of cases – Heredity, AD
- Association with hypertrichosis seen

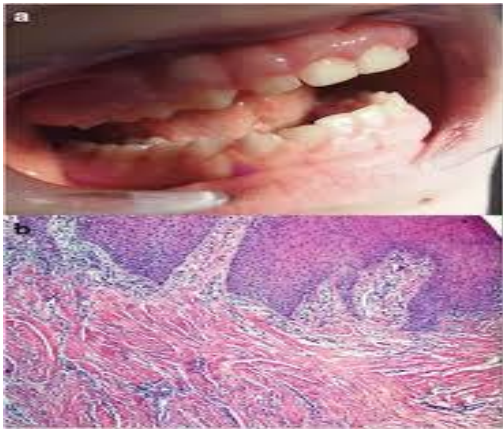
**C/F:**



- Birth or young children (perm incisor eruption)
- Firm, dense, non painful diffuse, smooth or nodular enlargements of gingiva, pale color
- Crowns of teeth may be hidden or eruption prevented

**H/F:**

- Fibrous hyperplasia
- Epithelium: Thick, elongated rete pegs
- CT: Forms bulk of tissue, coarse bundles of c
- Collagen with few fibroblasts & blood vessels



**Treatment:**

- Surgical excision
- In some cases tooth extraction alone causes its shrinking

**Retrocuspid Papilla**

- First described by Hirschfeld in 1933
- Small elevated nodule on lingual mucosa of mandibular cuspids

**C/F:**

- Commonly bilateral
- Lingual to mandibular cuspid, between free Gingiva & mucogingival junction

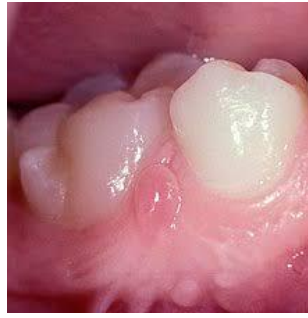**H/F:**

- Mucosal tag, Hyperkeratosis with or without acanthosis
- CT is highly vascular, large stellate fibroblasts
- Occasional Epithelial rests

**Treatment:**

in children, F>M Regresses with age, no treatment required





## **DEVELOPMENTAL ABNORMALITIES OF TONGUE**

### **Aglossia & Microglossia Syndrome:**

- Very rare
- Absence of tongue or presence of rudimentary tongue
- Usually associated with malformations in the extremities
- Difficulties due to the limited functions of the tongue

### **MACROGLOSSIA**

- Enlargement of tongue, Relatively uncommon disorder
- Etiology: Generalized and Localized, Meyer *et al*
- Localized:
  - ✓ Congenital - Hemangioma, Lymphangioma and Lingual thyroid
  - ✓ Inflammatory - Tuberculosis, Actinomycosis, Dental infection, Syphilitic gumma, Riga disease, Ranula, and Sublingual calculus
  - ✓ Traumatic -Dental irritation, Hematoma, and Postoperative edema
  - ✓ Neoplastic lesions-
    - ✚ Malignant- Carcinoma and Sarcoma
    - ✚ Benign - Granular cell tumor, Neurofibroma, Leiomyoma and
    - ✚ Lipoma.
- Generalized:
  - ✓ Congenital - Primary idiopathic macroglossia, Cretinism, Hemangioma, Lymphangioma, Robinow Syndrome, Beckwith-Weidmann Syndrome, Down Syndrome, 4P Syndrome, triploid Syndrome, Generalized gangliosidosis syndrome, and Mucopolysaccharidoses.



- ✓ Inflammatory - Chronic glossitis
- ✓ Traumatic - Postoperative edema
- ✓ Metabolic - Myxedema, Amyloidosis, Lipoid proteinosis, Steroid therapy, and Acromegaly

▪ **Clinical Significance:**

- ✓ Tongue protrusion, which exposes the tongue to trauma leads to mucosal drying and recurrent upper respiratory tract infections.
- ✓ Noisy breathing,
- ✓ Speech impediment,
- ✓ Swallowing difficulties,
- ✓ Drooling of saliva
- ✓ Airway obstruction (Patients with chronic airway obstruction may need CXR and ECG to evaluate right heart failure).

**Treatment:**

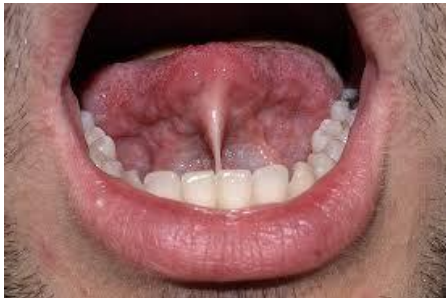- ✓ Successful treatment require appropriate rehabilitation and long term follow up.
- ✓ Treatment options varies from observation, orofacial therapy and surgery.
- ✓ In case of child Patients who have minimal symptoms may be observed since changes in tongue position as age advances may improve the disorder.
- ✓ In adults the initial treatment should be conservative but main treatment is partial glossectomy.

**ANKYLOGLOSSIA:**

- Ankyloglossia / Short frenum / Short frenulum / Tongue tie
- Restricted lingual frenum - Reduced mobility of the tongue
- Ankyloglossia occurs as a result of the fusion of the lingual frenum to the floor of the mouth.
- Partial ankyloglossia or "tongue-tie" is a much more common condition, because complete fusion rarely occurs.
- This leads to a myriad of speech problems such as lisping and stuttering, periodontal and swallowing problems and dental problems such as gap between mandibular incisors
- Ankyloglossia / Short frenum / Short frenulum / Tongue tie
- Restricted lingual frenum - Reduced mobility of the tongue
- Ankyloglossia occurs as a result of the fusion of the lingual frenum to the floor of the mouth.
- Partial ankyloglossia or "tongue-tie" is a much more common condition, because complete fusion rarely occurs.



- This leads to a myriad of speech problems such as lisping and stuttering, periodontal and swallowing problems and dental problems such as gap between mandibular incisors



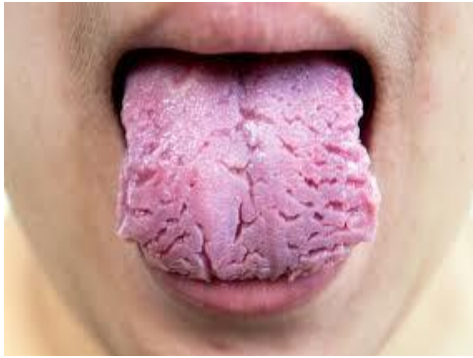### **CLEFT-TONGUE:**

- Cleft tongue is a condition where the tongue has a cleft running right across in the center of the tongue antero posteriorly.
- Complete clefting (Diglossia) is extremely rare and occurs as a result of lack of developmental forces to push both halves of the tongue towards each other.
- Partial clefting presents as a deep groove in the middle of the tongue and is a common feature in the oro-facial-digital syndrome (thick fibrous bands in lower anterior mucobuccal fold and clefting of hypoplastic mandibular alveolar process).
- Bifid tongue in association with Klippel-Feil anomaly and cleft palate has been reported.
- Cleft tongue is of little importance other than causing difficulty in eating as food gets stuck in the cleft causing irritation.

### **FISSURED TONGUE:**

#### **Synonyms:**

- Scrotal tongue
- Furrowed tongue
- Lingua fissurata
- Lingua plicata
- Lingua scrotalis
- Plicated tongue
- Cerebriform tongue
- Grooved tongue



### **Fissured tongue:**

- ✓ Grooves with varying depths along the dorsal and lateral aspects of the tongue.
- ✓ The depth of the fissures varies, up to 6 mm noted.
- ✓ The fissures or grooves may be interconnected, separating the tongue dorsum into several lobules.
- ✓ Definitive etiology is unknown .
- ✓ A polygenic or AD mode of inheritance is suspected because this condition is seen with increased frequency in families with an affected proband.
- ✓ In some cases, associated with infection or malnutrition or benign migratory glossitis .

- ✓ **Syndromes:**

- ✚ Melkersson-Rosenthal Syndrome
- ✚ Down syndrome is frequent

- ✚ Melkersson-Rosenthal syndrome is a rare condition ,Triad

- ❖ Persistent or recurring lip or facial swelling,
- ❖ Intermittent 7<sup>th</sup> (facial) nerve paralysis
- ❖ Fissured tongue

- ✓ Significance when seen in Melkersson-Rosenthal syndrome
- ✓ Morbidity not due to the fissured tongue but secondary to the granulomatous inflammation of the lips/facial soft tissues and facial paralysis.
- ✓ Some reports - slight Male predilection.
- ✓ Fissured tongue is a totally benign condition and is considered by most to be a variant of normal tongue architecture.
- ✓ The lesions are usually asymptomatic unless debris is entrapped within the fissure which causes irritation.
- ✓ The condition may be evident at birth (congenital) or become apparent during childhood or later and diagnosed more frequently in adulthood.
- ✓ The prominence of the condition appears to increase with increasing age.

- **Histology:**

- ✓ Hyperplasia of retepegs.
- ✓ Loss of keratin hairs on surface of filliform papilla.



- ✓ Papillae are separated by deep grooves.
- ✓ Micro abscesses in upper epithelial layers and polymorphonuclear infiltrate into epithelium.
- ✓ Mixed inflammatory infiltrate in the lamina propria.
- **Treatment:**
  - ✓ No specific treatment required.
  - ✓ Patients should be advised to brush tongue since grooves may act as a source of bacterial accumulation and cause irritation.

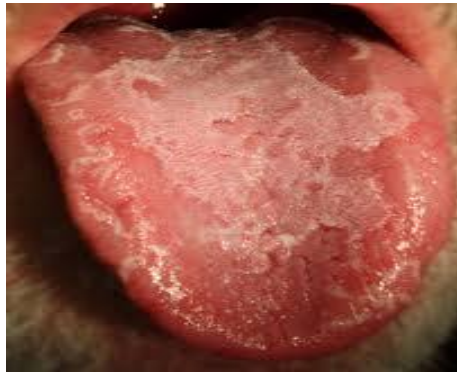## **GEOGRAPHIC TONGUE (Benign migratory glossitis)**

### **Erythema migrans / Psoriasisiform mucositis:**

- Benign condition, occurs in about 3% of the general population
- Etiology & pathogenesis -
  - ✓ Poorly understood
  - ✓ May be hypersensitivity or environmental or hormonal factors
- Although this is an inflammatory condition histologically, a polygenic mode of inheritance has been suggested because it is seen clustering in families.
- Associated with:
  - ✓ Human leukocyte antigen DR5 (HLA-DR5)
  - ✓ Human leukocyte antigen DRW6 (HLA-DRW6)
  - ✓ Human leukocyte antigen Cw6 (HLA-Cw6)
- Increased frequency in patients with fissured tongue & psoriasis
- Clinical features:
  - ✓ It can affect all age groups, Adults > Children
  - ✓ Females twice greater than Males
  - ✓ Patient Complaints:
    - ✚ Burning sensation or irritation of the tongue with hot or spicy foods
    - ✚ Discomfort that waxes and wanes over time
    - ✚ Lesions affect different areas of the tongue at different times
  - ✓ Classic manifestation: Area of erythema, with atrophy of the filiform papillae of the tongue, surrounded by a serpiginous, white, hyperkeratotic border.
  - ✓ Primarily affects the dorsum and often extending to involve the lateral borders of the tongue.
  - ✓ Similar lesions may be present concurrently on other aspects of the tongue or other mucosal sites.
  - ✓ Patients are concerned about the diagnosis of oral cancer, which prompts them to get evaluated, despite reporting that they have noted these lesions over many years.



- **Histology:**
  - ✓ Microscopically it is described as a psoriasiform mucositis
  - ✓ At the periphery, elongation of the rete ridges is noted with associated hyperparakeratosis and acanthosis
  - ✓ Toward the center of the lesion, corresponding to the erythematous area clinically, loss of filiform papillae with migration and clustering of neutrophils within the epithelium
  - ✓ The predominant inflammatory infiltrate in the lamina propria is neutrophils with an admixture of chronic inflammatory cells
- **Treatment:**
  - ✓ No medical intervention is required because the lesion is benign and most often asymptomatic.
  - ✓ In severe cases topical corticosteroids in the form of fluocinonide & beta methasone gel with zinc supplements can be prescribed.



### **MEDIAN RHOMBOID GLOSSITIS**

- Median rhomboid glossitis / Central Papillary Atrophy /Posterior Lingual Papillary Atrophy
  - Focal area of susceptibility to recurring or chronic atrophic candidiasis.
  - Prompting the use of Posterior Midline Atrophic Candidiasis as a more appropriate diagnostic term
  - Etiology: First suggested in 1914 by Brocq and Pautrier.
  - The embryonic tongue is formed by two lateral processes (lingual tubercles) meeting in the midline and fusing above a central structure from the second branchial arch (copula) with hypobranchial eminence.
  - During this period of fusion posterior dorsal point of fusion is occasionally defective, leaving a rhomboid-shaped, smooth erythematous mucosa lacking in papillae or taste buds derived from copula.



▪ **Clinical features:**

- ✓ The lesion is found in one of every 300-2,000 adults, depending on the rigor of the clinical examinations
- ✓ Shows 3:1 male predilection.
- ✓ Presents in the posterior midline of the dorsum of the tongue, just anterior to the V-shaped grouping of the circumvalate papillae.
- ✓ The long axis of the rhomboid or oval area of red depapillation is in the anterior-posterior direction.
- ✓ The erythematous clinical appearance is due to the absence of filiform papillae in this region rather than to local inflammatory changes .
- ✓ Typical lesions are less than 2 cm. in greatest dimension
- ✓ Most demonstrate a smooth, flat surface, sometimes surface may be lobulated
- ✓ Occasional lesions have surface papillations raised more than 5 mm above the tongue surface located somewhat anterior to the usual location. None have been reported posterior to the circumvalate papillae.
- ✓ Lesions associated with atrophic candidiasis are usually more erythematous but some respond with excess keratin production and, therefore, show a white surface change.
- ✓ Infected cases may also demonstrate a midline soft palate erythema in the area of routine contact with the underlying tongue involvement this is referred to as a kissing lesion.

▪ **Microscopy:**

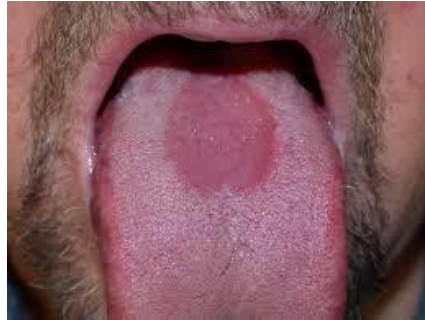- ✓ Silver staining & PAS for fungus will often reveal candida hyphae and spores in the superficial layers of the epithelium.
- ✓ Chronic candida infection may result in excess surface keratin or extreme elongation of rete processes and premature keratin production with individual cells or as epithelial pearls (dyskeratosis) deep in the processes.
- ✓ Pseudoepitheliomatous hyperplasia may be quite pronounced, and the tangential cutting of such a specimen may result in the artifactual appearance of cut rete processes as unconnected islands of squamous epithelium.
- ✓ Hence, it is recommended that the patient be treated with topical antifungals prior to biopsy of a suspected median rhomboid glossitis

▪ **Treatment:**

- ✓ No treatment is necessary for median rhomboid glossitis, but nodular cases are often removed for microscopic evaluation.
- ✓ Recurrence after removal is not expected, although those cases with pseudoepitheliomatous hyperplasia should be followed closely for at least a year after biopsy to be certain of the benign diagnosis.



- ✓ Antifungal therapy (topical or systemic medication) will reduce clinical erythema and inflammation due to candida infection.
- ✓ Some lesions will disappear entirely with antifungal therapy



### **Lingual thyroid gland:**

- Accessory accumulation of thyroid tissue that is usually functional within the body of the posterior tongue

#### **Etiopathogenesis:**

- Late in 1st month of IU life the anlage of the thyroid gland descends from the posterior dorsal midline of the tongue (actually the floor of the pharyngeal gut) to its final position in the lower neck.
- If the embryonic gland does not descent normally, ectopic or residual thyroid tissue may be found between the foramen caecum and the epiglottis.
- Approximately two-thirds of patients with lingual thyroid lack thyroid tissue in the neck.

#### **• Clinical features:**

- ✓ The lingual thyroid is four times more common in females than in males.
- ✓ It presents as an asymptomatic nodular mass of the posterior lingual midline, usually less than a centimeter in size but sometimes reaching more than 4 cm in size .
- ✓ Larger lesions can interfere with swallowing and breathing, but most patients are unaware of the mass at the time of diagnosis, which is usually in the teenage or young adult years.
- ✓ Up to 70% of patients with lingual thyroid have hypothyroidism and 10% suffer from cretinism.
- ✓ Other sites of ectopic thyroid deposition : Cervical lymph nodes, submandibular glands and the trachea. Rarely, parathyroid glands are associated with the ectopic thyroid tissue.

#### **• Histology:**

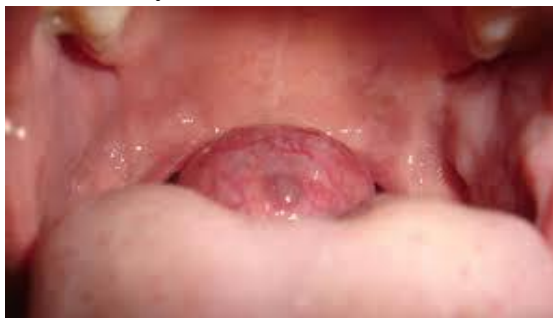



- ✓ The lingual thyroid consists of a non-encapsulated collection of embryonic or mature thyroid follicles which may extend between muscle bundles, raising suspicions of malignant invasion.
- ✓ The follicular cells are normal or atrophic in appearance.
- ✓ All diseases capable of affecting the normal thyroid gland can of course, affect the glandular tissue entrapped in the tongue.
- ✓ Thyroid adenoma, goiter, hyperplasia, inflammation, and carcinoma occur in lingual thyroids and therefore, be evaluated in the same fashion as would any biopsied thyroid gland.

- **Treatment:**

- ✓ Surgical excision or radioiodine therapy are effective treatments for lingual thyroid, but no treatment should be attempted until an <sup>131</sup>Iodine radioisotope scan has determined that there is adequate thyroid tissue in the neck.
- ✓ Endocrine evaluation for hypothyroidism should, therefore, be done in such cases. In this light, it is important to know that three of every four patients with infantile hypothyroidism have ectopic thyroid tissue
- ✓ Occasional patients with parathyroid tissue associated with their lingual thyroid have developed tetany after their inadvertent removal.
- ✓ In those patients lacking thyroid tissue in the neck, the lingual thyroid can be excised and autotransplanted to the muscles of the neck.
- ✓ However, Most cases require no treatment and in cases where biopsy is necessary it should be considered with caution because of the potential for hemorrhage, infection or release of large amounts of hormone into the vascular system (thyroid storm).
- ✓ Rare examples of thyroid carcinoma arising in the mass have been reported, almost always in males.



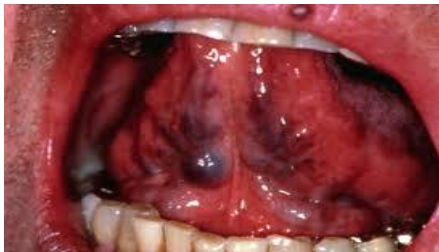### **LINGUAL VARICOSITIES**

- Prominent lingual veins, usually observed on the ventral and lateral surface of the tongue are called lingual varicosities.



- These are hemorrhoid (dilated veins) caused by the decrease in the amount of surrounding connective tissue.
- A normal variant in adults over 60 years of age believed to be related to the aging process.
- Its occurrence increases with age or increased blood pressure
- Enlarged veins usually purple or red or clusters on ventral and lateral surface of the tongue. There is no association with other systemic diseases; however, a relationship between varicosities in the legs and prominent lingual veins has been reported.
- **Microscopy** reveal dilated veins with walls showing little smooth muscle and poorly developed elastic tissue .
- Thrombosis show lines of Zahn which may result in recanalization or phlebolith formation

**Treatment** is not necessary.

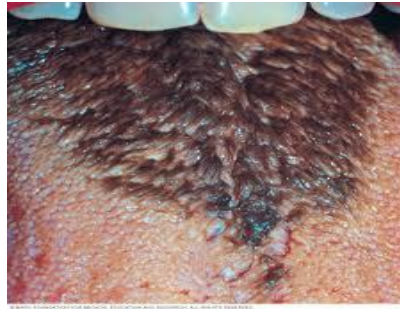


### **HAIRY TONGUE(Black Hairy Tongue / Lingua Villosa Nigra)**

- Commonly observed condition of defective desquamation of the filiform papillae that results from a variety of precipitating factors
- Tongue may also appear brown, white, green, pink, or any of a variety of hues depending on the specific etiology and secondary factors
- **Etiology:**
  - ✓ Basic defect in hairy tongue is a hypertrophy of filiform papillae on the dorsal surface of the tongue, with a lack of normal desquamation.
  - ✓ Contributory factors for hairy tongue are numerous and include poor oral hygiene, tobacco use, coffee or tea drinking, the use of medications (especially broad-spectrum antibiotics) and therapeutic radiation of the head and the neck.
- **Clinical features:**
  - ✓ Normal filiform papillae 1 mm in length, in hairy tongue more than 15 mm in length.
  - ✓ Hairy tongue is rarely symptomatic, although overgrowth of *Candida albicans* may result in glossopyrosis (burning tongue).



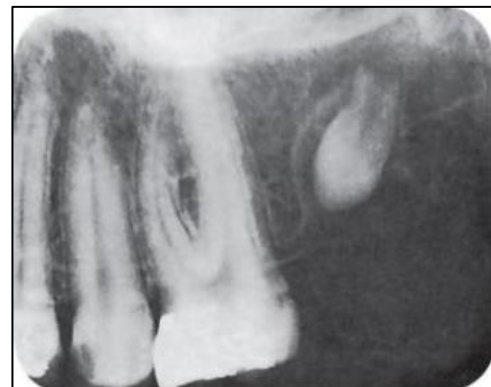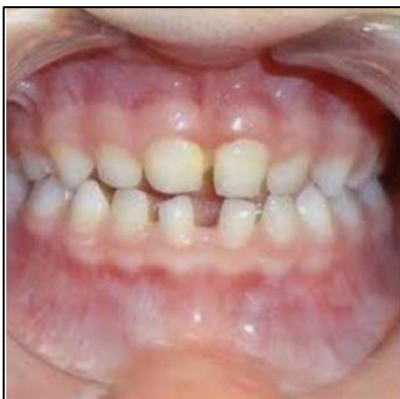- ✓ Patients frequently complain of a tickling sensation in the soft palate and the oral pharynx during swallowing.
  - ✓ In more severe cases, patients may actually complain of a gagging sensation. Retention of oral debris between the elongated papillae may result in halitosis.
  - ✓ Although hairy tongue is reported more often in males, it is not uncommon in females, especially those who drink coffee or tea and/or those who use tobacco.
  - ✓ The incidence and the prevalence of hairy tongue increases with age.
  - ✓ Patients occasionally notice the condition of the tongue during tooth brushing and present to the office with concerns regarding potential malignancy.
  - ✓ The tongue has a thick coating in the middle, with a greater accentuation toward the back.
  - ✓ Bacterial and fungal overgrowth play a role in the color of the tongue.
  - ✓ In extreme cases of hairy tongue, a blast of compressed air results in the papillae "waving in the breeze."
- **Histology:**
    - ✓ Consist of elongated filiform papillae, with mild hyperkeratosis and occasional inflammatory cells.
    - ✓ Finding accumulated debris intermingled among the papillae and candidal pseudohyphae is not unusual.
    - ✓ Culture of the tongue's dorsal surface may be taken if a superimposed oral candidiasis or other specific oral infection is suspected.
    - ✓ Cytologic smears stained with Gram stain or periodic acid-Schiff stain may reveal candidal organisms.
    - ✓ Distinguishing between oral hairy leukoplakia and hairy tongue is important if patients are found or suspected to be HIV positive.
    - ✓ This can be accomplished by checking clinical response to mechanical debridement or a simple mucosal biopsy or appropriate immunostaining of the specimen for the presence of Epstein-Barr virus.
  - **Treatment:** Treatment of hairy tongue is variable.
    - ✓ In many cases, simply brushing the tongue with a toothbrush or using a commercially available tongue scraper is sufficient to remove elongated filiform papillae and retard the growth of additional ones.
    - ✓ Surgical removal of the papillae by using electrodesiccation, carbon dioxide laser or even scissors is the treatment of last resort when less complicated therapies prove ineffective.



## **DEVELOPMENT ANOMALIES IN SIZE OF TEETH**

### **I. MICRODONTIA:**

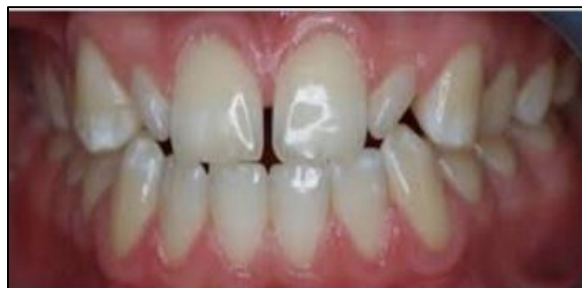- It refers to teeth which are smaller than normal size.
- There are 3 types of Microdontia-
  1. **True-generalised Microdontia-**
    - + All the teeth are smaller than normal.
    - + Occurs in cases of endocrinal disturbances (pituitary dwarfism).
  2. **Relative-generalised Microdontia-**
    - + The teeth may be of normal size/smaller but due to large jaw, they give illusion of small tooth.
  3. **Microdontia involving single teeth-**
    - + Localised microdontia seen.
    - + Most common in cases of maxillary lateral incisor and 3<sup>rd</sup> molar.  
Eg:- Supernumerary tooth with peg laterals or screw shaped incisors.
- **Management:** Crown and Bridge placement for aesthetic rehabilitation.





## **II. MACRODONTIA:**

- It refers to teeth which are larger than normal.
- There are 3 types of Macrodonia:
  1. **True-Generalised Macrodonia-**
    - ✚ All teeth are larger than normal and are associated with pituitary dwarfism.
  2. **Relative Generalised Macrodonia -**
    - ✚ Seen in cases of micrognathic jaw, teeth may be Larger or normal in size.
  3. **Macrodonia of single tooth-**
    - ✚ Localised macrodonia may be seen in Taurodontism.
- **Clinical Features:**
  - ✚ Malocclusion may occur
  - ✚ Impactions may occur
- **Management:**
  - ✚ Orthodontic treatment.
  - ✚ Extraction of impacted teeth.

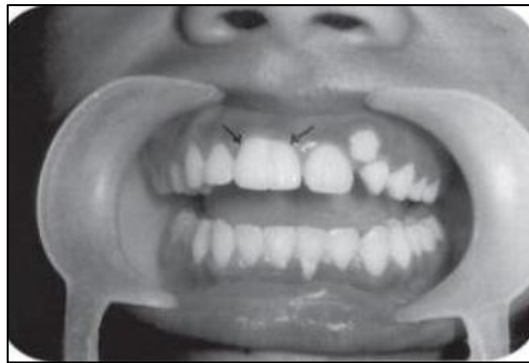

## **DEVELOPEMENTAL ANOMALIES OF SHAPE OF TEEETH**

### **I. Gemination:**



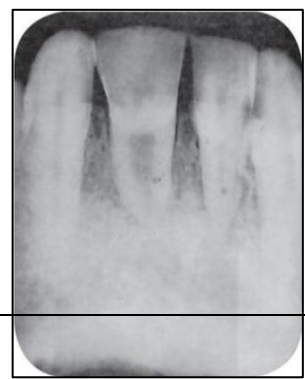- It is developmental anomaly in shape of teeth.
- Geminated tooth arises from an attempt of single tooth bud divide by invagination, leading to incomplete formation of 2 teeth.
- The resultant structure has 2 completely or incompletely separated crowns with single root and pulp/root canal.
- Most common in deciduous mandibular incisor and permanent maxillary incisors.
- **Twinning**: refers to complete separation with single root and root canal as a result of which 2 small teeth are seen in the oral cavity. Out of which one is normal and supernumerary teeth.
- **Management**:
  - i. Reduction in mandibular width by dissecting.
  - ii. Jacket crown preparation.

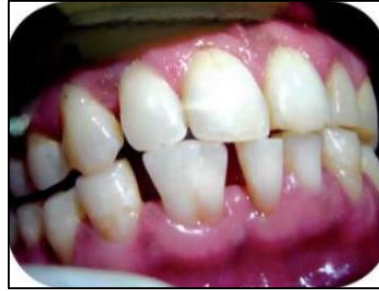
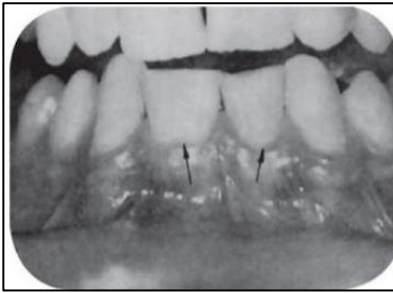
## II. Fusion:

- It is a developmental anomaly in shape of tooth.
- Fusion is the union of two adjacent tooth germ at the level of dentin (confluent) during development.
- Fusion occurs due to pressure or physical forces leading to joining together of two adjacent tooth germs.
- Depending upon the stage of development of tooth, fusion can be:
  1. Complete: before calcification, the crowns and roots are fused.
  2. Incomplete: in later stages of odontogenesis as a result the roots are only fused with separated crown.
- Fusion may also occur between a normal tooth and supernumerary tooth as in case by mesiodens and distomolar.

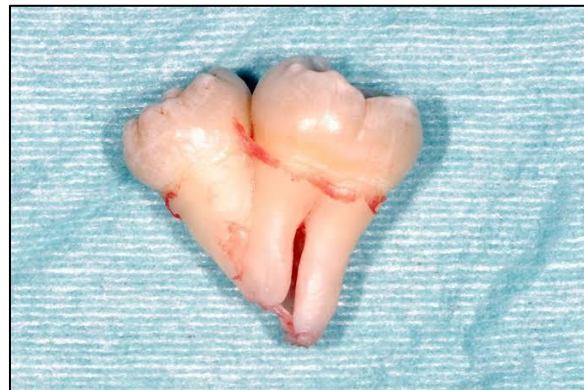**Treatment**: Endodontic management.





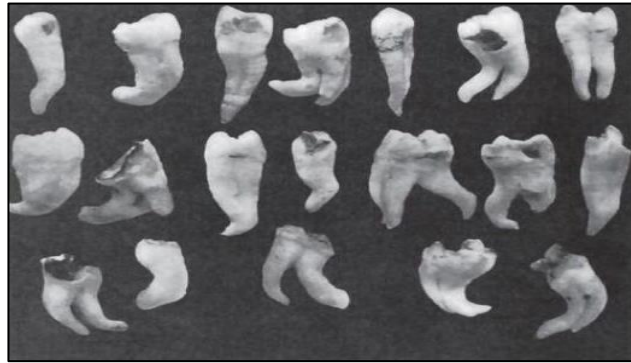
### **III. Concrecence:**

- It is a type of fusion which occurs after complete root formation.
- The teeth are united by cementum only.
- It occurs due to traumatic injury/crowding of teeth resulting in resorption of interdental bone leading to approximation of adjacent teeth roots and formation of cementum between them.
- Clinical significance is during extraction, the other tooth may also get extracted and leads to trauma if radiographic features not taken. (common in maxillary molars)



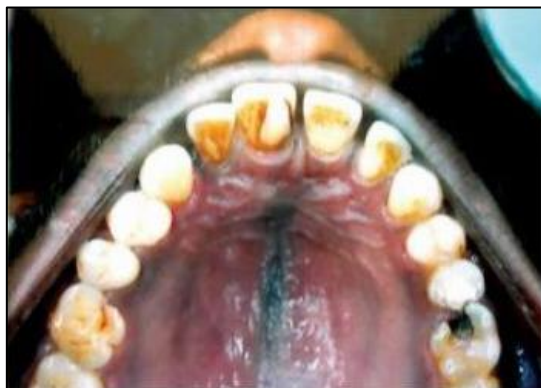### **IV. Dilacerations:**

- It refers to angulations/sharp bend/ curve in the root/crown of formal tooth.
- It occurs due o trauma during odontogenesis as a result the position of the calcified portion of tooth is changed and remainder of tooth is formed at an angle.
- Dilacerations may occur at any point, along the length of root (at apex/ at midway/ at cervical region).
- Clinical significance is during extraction, difficulty in extraction.



#### V. Talon's cusp:

- It is a projection/protuberance arising from the cingulum area of maxillary/Mandibular permanent incisors.
- It is so called because it resembles the eagle's claw/ talon.
- It is composed of normal enamel, dentin and pulp horn.
- It is commonly seen in cases of Rubinstein-Taybi syndrome.
- It is more prone to caries, occlusal interferences.
- **Management:** It should be removed followed by endodontic and restorative treatment.



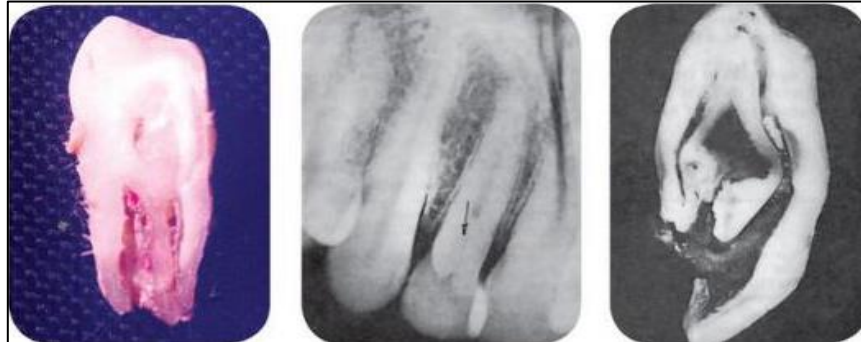
#### VI. Dens-In-Dente (DENS-INVAGINTUS):

- It is an anomaly in which the localised area of tooth is folded/invaginated pulpally.
- Most common in maxillary lateral incisors.
- It is of 2 types:
  1. Coronal type: invagination/ folding occur in crown portion, caused due to invagination of 1<sup>st</sup> crown formation.
  2. Radicular type: invagination occurs in root portion of tooth due to folding of Hertwig's Epithelial Root Sheath(HERS) during root formation.



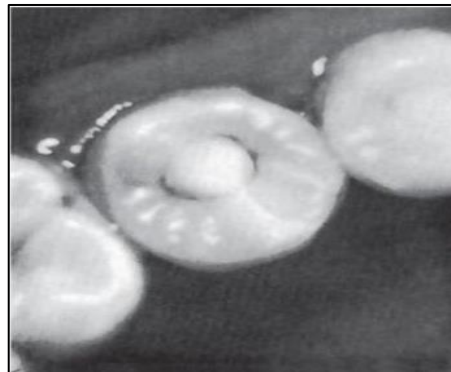

- Radiographically it appears as a ‘Pearl-shaped’ invagination of enamel or dentin.
- It acts as an area of accumulation of food debris and leads to dental caries if not restored at early period.



### **VII. Dens Evaginatus (Evaginated Odontome, Occlusal Enamel Pearl):**

- It appears as an “accessory cusp” or globule of enamel on the occlusal surface between the buccal and lingual cusp of premolars (Uni/Bi laterally).
- It occurs due to localised evagination of IEE odontogenesis mesenchyme into the dental organ.
- It causes occlusal interference and due to attrition/ fracture the pulp may get exposed, so it has to endo-dentically treated.
- Clinically resembles “Talon-cusp” and has normal enamel, dentin and pulp horn.

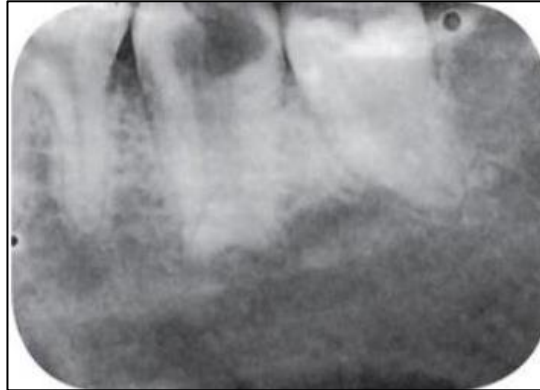

### **VIII. Taurodontism (Bull like) :**

- It is a condition in which the crown portion of tooth is enlarged at the expense of its roots.
- The teeth are rectangular in shape with minimal constriction at cervical area.
- Furcation area of root is more apically placed.
- Teeth have greater “Apico-occlusal height”.
- It is more common in multi-rooted teeth.

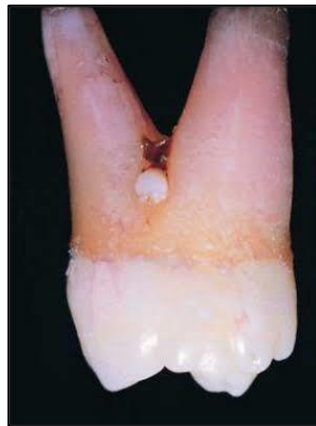

- It is commonly associated with Down's syndrome and Klinefelter's syndrome.
- The condition occurs due to failure of HERS to invaginate at proper horizontal level.



### ***IX. Enamel pearl:***

- These are white, dome shaped, calcified projection of enamel located at furcation are of molar teeth.
- Most commonly seen in maxillary molars.
- It arises which HERS retain its ameloblastic potential and synthesise enamel in some focal areas, in a place of cementum.



### ***Rhizomicri***

- It is a condition where root of the teeth are smaller than normal
- Teeth most commonly affected are maxillary laterals, maxillary 3<sup>rd</sup> molars, maxillary & mandibular 1<sup>st</sup> premolars
- Clinical significance
  - Involved tooth cannot be used as anchorage & abutment .

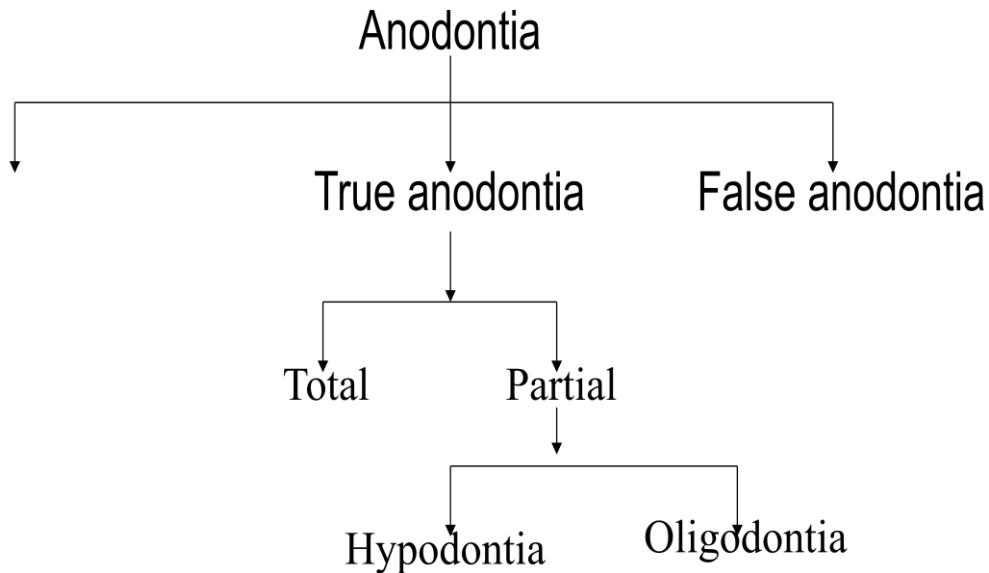


### ***Rhizomegaly (Radiculomegaly)***

- It is a condition where in root of the teeth is larger than normal
- Most commonly affected teeth are maxillary & mandibular cuspids
- Clinical significance:
  - Extraction difficulties
  - Oro-antral fistula

### **Developmental disturbance in the number of teeth**

Anodontia : Types

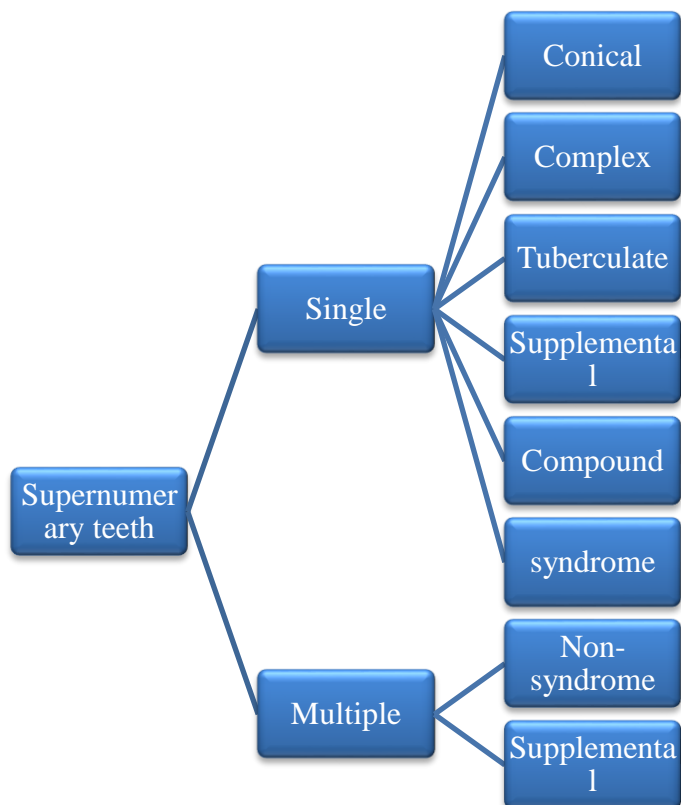


- **Pseudo anodontia:** Condition in which teeth are present within the jaw bones but are not erupted.
- E.g.
  - Impacted tooth
  - Embedded tooth
- **False anodontia:** Condition in which the teeth are missing in oral cavity due to extraction or exfoliation .



- **True anodontia:** Condition which occurs due to failure of development of tooth in the jaw bones .
- Can be total or partial
  - Hypodontia: Congenital absence of one or more teeth but less than 6
  - Oligodontia: Congenital absence of one or more teeth but more than 6
- Conditions & syndromes associated:
  - Hereditary ectodermal dysplasia
  - Down syndrome
  - Book's syndrome
  - Ehler's – Danlos syndrome
  - Rieger's syndrome
  - Supernumerary teeth (Hyperdontia)
  - Presence of tooth in excess of the normal number in the dental arch
- **Etiology:**
  - Accessory tooth bud
  - Splitting of the regular normal tooth bud
  - Hereditary
  - Atavism

I. Based on number and shape:





## II. Based on location :

- **Mesiodens:**
  - ✓ Most common type of supernumerary tooth
  - ✓ Located between the upper central incisors
  - ✓ Small conical in shape
  - ✓ Erupted / impacted / inverted
  
- **Distomolar :**
  - ✓ Small rudimentary tooth
  - ✓ Located distal to 3<sup>rd</sup> molars in the dental arch
  
- **Paramolar:**
  - ✓ Small rudimentary tooth
  - ✓ Located on buccal / lingual aspect of the normal molars
  - ✓ Clinical features:
    - ✚ Crowding, malocclusion & aesthetic problems
    - ✚ May lead to increased incidence of dental caries & periodontal problems
    - ✚ Dentigerous cyst may develop from impacted supernumerary tooth
  - ✓ Treatment:- Extraction

### Conditions & syndromes associated:

- Cleido cranial dysplasia
- Cleft lip & palate
- Gardner's syndrome (multiple supernumerary teeth)
- Down's syndrome
- Apert syndrome
  
- **Gardeners syndrome:**
  - ✓ Supernumerary teeth
  - ✓ Multiple polyposis of the large intestine
  - ✓ Osteomas of the bones – long bones , skull and jaw bones
  - ✓ Multiple epidermoid or sebaceous cysts of the skin ( scalp and back)
  - ✓ Impacted supernumerary and permanent teeth

## III. **Predeciduous dentition:**

- ✓ Infants occasionally are born with structures which appear to be erupted teeth
- ✓ Earlier thought to arise from accessory bud from accessory dental lamina & the concept is no more in use
- ✓ Now thought as hornified epithelial structures filled with keratin occurring on gingiva on crest of ridge & are termed as 'dental lamina cyst of new born



#### **IV Post permanent dentition :**

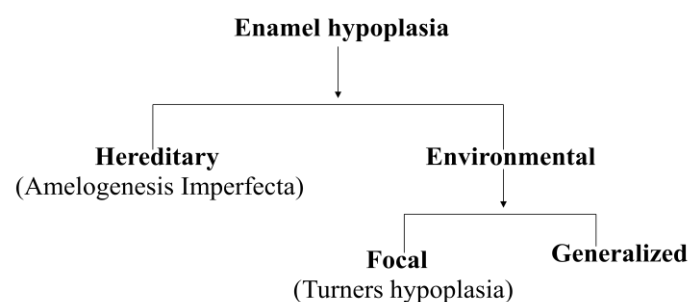
- ✓ It is a condition in which several teeth erupt into oral cavity after all permanent teeth are lost particularly after the insertion of full denture
- ✓ Earlier it was thought to be the third dentition
- ✓ Now it is regarded as the delayed eruption of embedded or impacted permanent teeth or it can be eruption of multiple supernumerary unerupted teeth

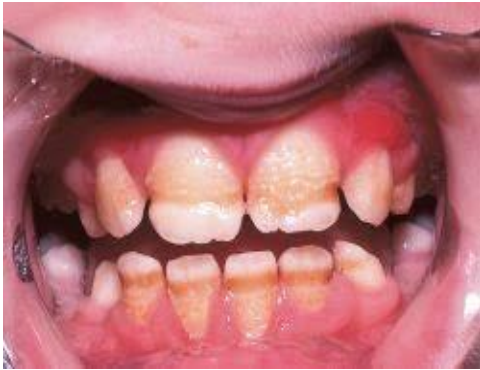#### **Developmental disturbances in the structure of teeth:**

- **Enamel :**
  - Enamel hypoplasia
  - Amelogenesis imperfecta
- **Dentin :**
  - Dentinogenesis imperfecta
  - Dentin dysplasia
- **Enamel + Dentin:**
  - Regional odontodysplasia
- **Cementum :**
  - Hypocementosis
- **Enamel hypoplasia:**
  - It's a the defect of enamel & the defect is due to disturbance during its formative process
  - During the formative stages of enamel the ameloblast cells are susceptible to various factors which can disturb the process & the effect of which is reflected on the surface enamel after the eruption of tooth

Types:

• **Based on causative factors:**





### ***Amelogenesis Imperfecta :***

- It is a heterogenous group of hereditary disorders of enamel formation
- The condition involves only the enamel while dentin, cementum & pulp remain normal
- Types :
  - Amelogenesis imperfecta may set in during any stage of enamel formation. Based on that there are 3 types
    - ✓ Hypoplastic type
    - ✓ Hypocalcification type
    - ✓ Hypomaturation type
  - Hypoplastic type :
    - ✓ The disease affects the stage of matrix formation
    - ✓ Teeth exhibit complete absence of enamel or there may be presence of enamel on some focal areas
    - ✓ Enamel thickness is usually below normal
  - Hypocalcification type :
    - ✓ The disease affects the stage of early mineralization
    - ✓ Enamel is of normal thickness
    - ✓ Enamel is soft & can be easily removed with a blunt instrument
  - Hypomaturation type :
    - ✓ The disease affects the stage of maturation
    - ✓ Enamel is of normal thickness
    - ✓ Enamel does not have normal hardness & translucency & can be pierced with an explorer tip with firm pressure



## Witkop 1989: AI Classification

### Type 1: Hypoplastic (60-73%)

- 1A – Hypoplastic, pitted AD
- 1B – Hypoplastic, Local AD
- 1C – Hypoplastic, Local AR
- 1D – Hypoplastic, Smooth, AD
- 1E – Hypoplastic, Smooth, X-linked
- 1F – Hypoplastic, Rough, AD
- 1G – Enamel agenesis, AR

### Type 2: Hypomaturation (20-40%)

- II A – Hypomaturation, pigmented AR
- II B – Hypomaturation, X linked Recessive
- II C – Snow capped teeth, AD

### Type III: Hypocalcified (7%)

- III A – AD
- III B – AR

### Type IV: Hypomaturation-Hypoplastic with taurodontism

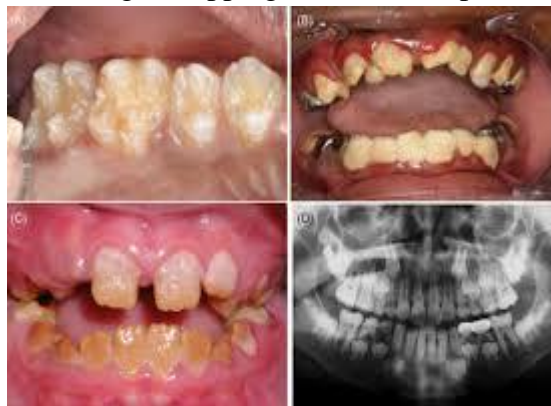#### Genetic Cause

- **Molecular genetic studies:**
  - ❖ DXS85 at Xp22 – gene location for amelogenin
- **Clinical features :**
  - ✓ It affects both deciduous & permanent dentition
  - ✓ Colour of the teeth varies from chalky white to yellow or dark brown
  - ✓ Teeth may be completely devoid of enamel or may have a cheesy consistency or may look normal except for presence of grooves on its surface
  - ✓ Occlusal surfaces & incisal edges are severely abraded
  - ✓ Snow capped teeth
  - ✓ It is the mildest form of hypomaturation type of amelogenesis imperfecta
  - ✓ The enamel is of near normal hardness & has some white opaque flecks at the incisal areas of the teeth





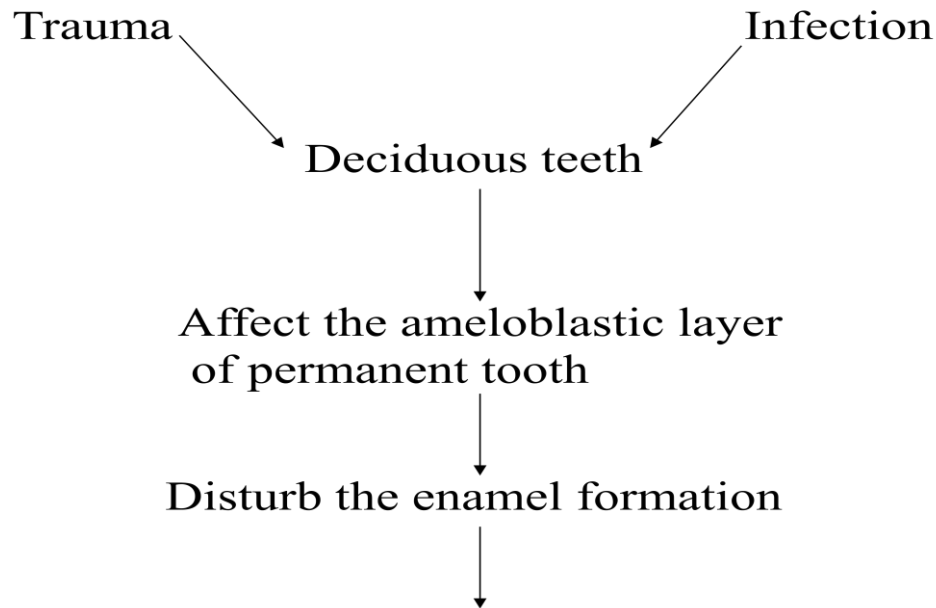
- Radiological features:
  - ✓ The thickness & radio density of enamel varies greatly
  - ✓ **Hypoplastic type** – Radiodensity of enamel is usually greater than dentin
  - ✓ **Hypomineralized type** – Radiodensity of enamel is lesser than dentin
  - ✓ **Hypomaturation type** – Radiodensity is equal to that of dentin
- Histopathology:
  - ✓ **Hypoplastic type** – Lack of differentiation of ameloblast cells with little or no matrix formation
  - ✓ **Hypocalcification type** – Abnormal mineral deposition
  - ✓ **Hypomaturation type** – Alteration in the enamel rod & rod sheath structures
- Treatment :
  - ✓ No definitive treatment
  - ✓ Veneering or capping of teeth to improve esthetics



### **Focal enamel hypoplasia:**

- Also known as Turner's hypoplasia
- Most common form of enamel hypoplasia
- Occurs due to trauma or infection to deciduous teeth
- Usually affects single tooth & is called as Turners tooth
- Frequently involved teeth are permanent bicuspids & maxillary incisors

### **Pathogenesis:**



- **Clinical features:**

- ✓ Affected area of tooth appear as a zone of white or yellow brown discoloration & pitted areas
- ✓ Generalized enamel hypoplasia
- ✓ The ameloblasts in the developing tooth germ are sensitive to external stimuli
- ✓ Any systemic or environmental disturbance can result in abnormalities in enamel formation which manifests as defects on the surface of tooth
- ✓ It affects numerous teeth which are being formed at the time of disturbance
  
- ✓ Clinically the defects can manifests as
  1. Hypoplasia
  2. Diffuse opacities
  3. Demarcated opacities
- ✓ Most often it manifests as a horizontal line of enamel hypoplasia with pits & grooves
- ✓ The line on the tooth surface indicates the zone of enamel hypoplasia
- ✓ The location of the line corresponds with the developmental stage of affected tooth & width indicates the duration of the disturbances

- **Causes**

- ✓ **Prenatal**

- ✚ Infections (Rubella, Syphilis)
- ✚ Malnutrition, Metabolic & Neurological disorders during pregnancy
- ✚ Chromosomal abnormalities



+ Excess chemical intake (Tetracycline, Fluoride)

✓ **Neonatal**

- + Birth injury
- + Premature delivery
- + Prolonged labor
- + Low birth weight

✓ **Postnatal**

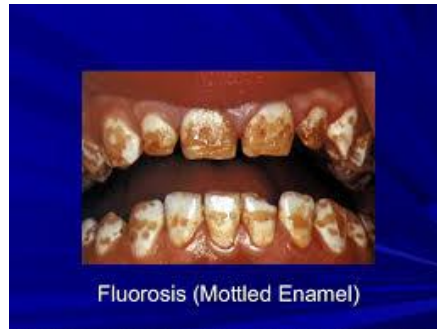
- + Severe childhood infections (Viral exanthematous fever)
- + Congenital heart diseases
- + Nutritional deficiencies (Vit-B, Vit-D)
- + Endocrinal disorders

- Enamel Hypoplasia due to syphilis:
  - ✓ Due to congenital syphilis
  - ✓ Not pitting variety
  - ✓ Permanent teeth involved
  - ✓ Anterior teeth – Hutchinson`s teeth (Screw driver teeth)
  - ✓ Posterior, Molars – Mulberry or Moon`s or Fournier`s molars
- Enamel Hypoplasia due to Hypocalcemia (Tetany):
  - ✓ Serum calcium levels – 6 to 8mg/100ml
  - ✓ Pitting variety of hypoplasia
- Enamel Hypoplasia due to Fluoride
  - ✓ Also called Mottled Enamel
  - ✓ GV Black & Frederick S McKay in 1961
  - ✓ Ingestion of fluoride containing water during tooth formation
  - ✓ Severity increases with increased levels of fluoride
  - ✓ 0.9-1.0 part per million, permissible level in drinking water
  - ✓

**Mottled Enamel**

**C/E:**

- ✓ Questionable changes – occasional white flecking or spotting of enamel
- ✓ Mild changes – white opaque areas involving larger tooth surface area
- ✓ Moderate to Severe – Pitting & Brownish staining
- ✓ Corroded teeth



### **Dentinogenesis Imperfecta :**

- ✓ A hereditary defect consisting of opalescent teeth composed of irregularly formed and undermineralized dentin that obliterates the coronal and root pulpal chambers.
  - ✓ Autosomal dominant mode of transmission
  - ✓ Also known as 'Hereditary opalescent dentin' / 'Shell teeth'
- 
- Types – Sheild`s et al, 1973
  - **Type I** – Associated with osteogenesis imperfecta,
    - blue sclera
  - **Type II** – Without osteogenesis imperfecta , most common
  - **Type III** – Brandywine type, racial isolated area in the state Maryland, multiple pulpal exposure in deciduous dentition
- 
- Chemical & Physical Features
    - **DI 1:** Water content increased, above 60% normal & Inorganic content lesser than normal density, X-Ray absorption & Hardness are low, almost that of cementum Therefore rapid attrition of teeth .
- 
- Clinical features:
    - ✓ Affects both the deciduous & permanent dentitions
    - ✓ Teeth exhibits an opalescent amber-like / gray or brownish appearance
    - ✓ Bluish reflection from enamel
    - ✓ Enamel is normal but fractures and chips away easily leads to exposed dentin and functional attrition
    - ✓ Teeth are not particularly sensitive & are not caries prone
    - ✓ Type I cases exhibit several bony defects & blue sclera
    - ✓ Type III cases exhibits multiple pulp exposures & periapical lesions
- 
- Radiological features :
    - ✓ Type I & II are similar & exhibit bulb-shaped or bell shaped crowns with constricted CEJ
    - ✓ Thin & spiked roots



✓ Obliteration of coronal & radicular pulp chamber

▪ Histopathological features

- ✓ Enamel & mantle dentin are normal
- ✓ Remaining dentin is severely dysplastic & exhibits vast areas of inter-globular dentin
- ✓ Dentinal tubules are disoriented, irregular, widely spaced
- ✓ Smooth DEJ



▪ Treatment:

- ✓ Treatment is aimed at preventing excessive tooth attrition & improving esthetics
- ✓ Metal or ceramic crowns & over dentures can be given

• Dentin dysplasia:

- ✓ A hereditary defect characterized by defective dentin formation & abnormal pulpal morphology
- ✓ Autosomal dominant disorder
- ✓ Also known as '**Root less teeth**'



Clinical Features:

Type I	Type II
Disturbance in development of radicular dentin	Disturbance in development of coronal dentin
Normal crowns both structurally & morphologically	Semi-transparent opalescent primary teeth Normal appearance in the permanent teeth
Color of teeth normal with slight bluish translucency in cervical region	Amber – grey color
Affected teeth exhibits short roots, delayed eruption, severe mobility & premature exfoliation 	



- Types :
  - ✓ **Type I** – Radicular dentin dysplasia
  - ✓ **Type II** – Coronal dentin dysplasia

- **Radiological features :**

<b>Type I</b>	<b>Type II</b>
Rudimentary or extremely short roots Mandibular molars exhibit ‘W’ shaped roots	Permanent teeth exhibits abnormally large flame shaped pulp chamber with pulp stones
Obliterated pulp chambers and root canals, before eruption	Deciduous teeth shows complete obliteration of pulp chambers and root canals, after eruption
Periapical radiolucencies around the defective roots	Absence of periapical radiolucencies
	

- Histopathological features:

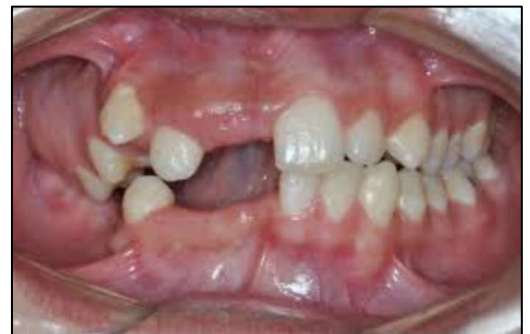<b>Type I</b>	<b>Type II</b>
Normal enamel and coronal dentin	Normal enamel and radicular dentin with partial obliteration of root canals



Radicular dentin is tubular, amorphous, and hypertrophic	Near normal coronal dentin with numerous areas of interglobular dentin near the pulp
Remnants of pulp tissue seen between normal & abnormal dentin which gives the appearance of “a series of sand dunes” or “lava flowing around boulders”	Abnormally large pulp chambers with pulp stones

### **Regional odontodysplasia:**

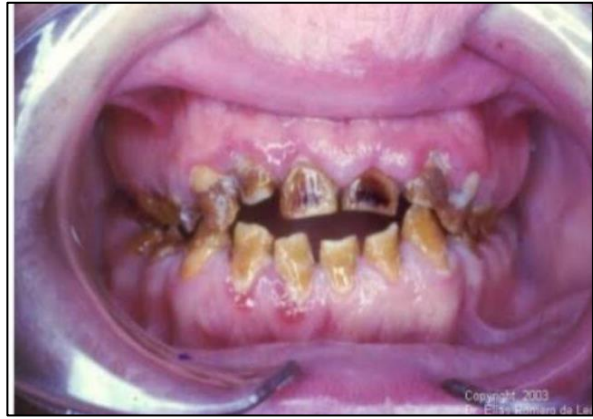- ✓ It is a uncommon non-hereditary developmental disturbances of tooth characterized by defective formation of enamel & dentin with abnormal calcifications of pulp & follicle
- ✓ Also known as “**Ghost teeth**”
- **Cause:**
  - Local ischemic change during odontogenesis
- **Clinical features :**
  - ✓ More common in permanent dentition
  - ✓ More common in maxilla
  - ✓ Affects several teeth in a single quadrant
  - ✓ Maxillary anterior teeth affected more
  - ✓ Failure of eruption or delayed eruption of affected teeth
  - ✓ Teeth are deformed, yellowish – brown in color with a soft leathery surface
- **Radiological features :**
  - ✓ Marked decrease in radio density of teeth
  - ✓ Enamel & dentin are very thin & radiological distinction not possible
  - ✓ Extremely large & open pulp chamber with pulp stones
  - ✓ Ghostly appearance of affected teeth
- **Histopathological features:**
  - ✓ Abnormal enamel & dentin
  - ✓ Large pulp chamber with pulp stones
  - ✓ Calcification in follicular connective tissue



### **Dentin Hypocalcification:**



- Failure of union of the globules on dentin during calcification leaving lot of interglobular areas with uncalcified matrix
- Softer than regular dentin
- Similar environmental causes as enamel hypoplasia



## **Disturbances of growth(eruption) of teeth:**

### **1. Premature eruption :**

- ✓ Tooth erupts into oral cavity much earlier than normal time of eruption
- ✓ Frequently involved tooth are deciduous mandibular central incisors
- **Types:**
  - ✓ Natal teeth – Erupted deciduous teeth present at the time of birth
  - ✓ Neonatal teeth – Deciduous teeth which erupt within first 30 days of life
- **Causes :**
  - ✓ Endocrinal disturbances :Adreno-cortical syndrome, Hyperthyroidism
  - ✓ Premature loss of deciduous teeth causes premature eruption of permanent teeth

### **2. Delayed eruption:**

- ✓ Tooth erupts into oral cavity much later than normal time of eruption
- ✓ Affects both deciduous & permanent dentition
- **Causes:**
  - ✓ **Systemic factors**
    - ✚ Rickets
    - ✚ Cleidocranial dysplasia
    - ✚ Cretinism
  - ✓ **Local factors**
    - ✚ Fibromatosis gingivae
    - ✚ Cleft lip & palate





## Retained deciduous tooth

- ✓ **Idiopathic**

### **Impacted teeth :**

- ✓ Are those teeth which are prevented from eruption into oral cavity by some physical barrier in eruptive path or non availability of space

- **Causes :**

- ✚ Micrognathia
- ✚ Retained deciduous teeth
- ✚ Supernumerary teeth
- ✚ Odontogenic cyst & tumors
- ✚ Cleft palate
- ✚ Syndrome associated

- **Classification :**

- ✓ **Completely impacted tooth** – Impacted tooth is totally surrounded by bone
- ✓ **Partially impacted tooth** – Impacted tooth is partly surrounded by bone & partly by soft tissue
- ✓ Mesioangular – Impacted tooth mesially inclined
- ✓ Distoangular – impacted tooth distally inclined
- ✓ Vertical – Impacted tooth lies vertical
- ✓ Horizontal – Impacted tooth lies horizontal

- **Complications:**

- ✓ Crowding
- ✓ Malocclusion
- ✓ Pericoronitis
- ✓ Radiating pain
- ✓ Root resorption of adjacent erupted teeth
- ✓ Food impaction & halitosis
- ✓ Dentigerous cyst

- **Treatment:-**

- ✓ Removal of cause
- ✓ Surgical removal

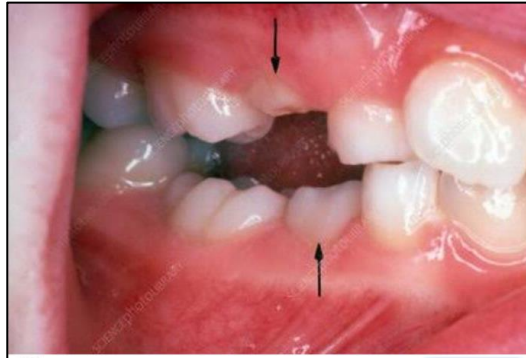
### **Embedded teeth:**

- ✓ It refers to those teeth that are unerupted due to lack of eruptive forces



### **Submerged teeth:**

- ✓ It refers to ankylosed deciduous teeth
- ✓ Frequently involved teeth are deciduous molars
- ✓ Occlusal table of the ankylosed deciduous tooth is located below the occlusal plane of the rest of the permanent teeth in the arch giving an submerged appearance
- ✓ In such cases the underlying permanent tooth may become impacted or may erupt either buccally / lingually



### **Eruption Sequestrum:**

- ✓ Anomaly associated with eruption of teeth in children
- ✓ Tiny irregular speck of bone on crown of erupting perm molar, on central fossa
- ✓ As tooth erupts through mucosa, it is lost
- ✓ R/F:
  - ✚ Tiny irregular opaque bit on the centre of occlusal surface
  - ✚ Due to corkscrew mechanism of tooth eruption within bone
- ✓ Significance: Soreness while eating, no treatment

