



## DENTAL IMPLANTS : PERIODONTAL CONSIDERATIONS

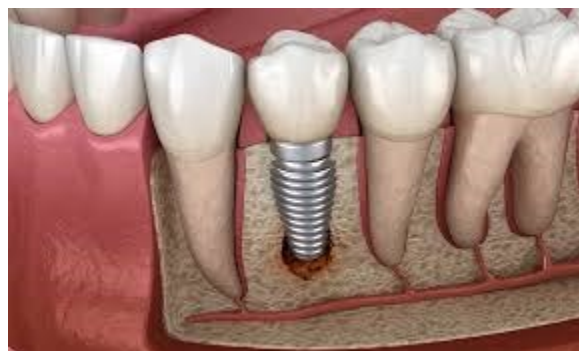Implant Dentistry has been the fastest growing treatment modality in dentistry for the past 20 years. The success in using dental implant to support dental restorations and reconstructions has been underpinned by the predictable formation of a bone-to-titanium interface (osseointegration) after the insertion of a titanium implant into the human jawbone. As a result, the titanium implant becomes a rigid extension of the jaw and can be utilized as a stable foundation to support dental restorations and enable normal function of mastication to be carried out by the patient in comfort over long periods of time.

### **Biological consideration in implant therapy Include**

- **Soft tissue**
- **Bone**

Healthy soft tissue surrounding a dental implant is essential for health, function, and esthetics. The development of the tooth includes the formation of a biologic connection between the living tissues that has to be created during the healing process after placement of the implant. The success of dental implants is dependent on the establishment of a soft-tissue barrier that is able to shelter the underlying osseous structures and the osseointegration surrounding the implant body.

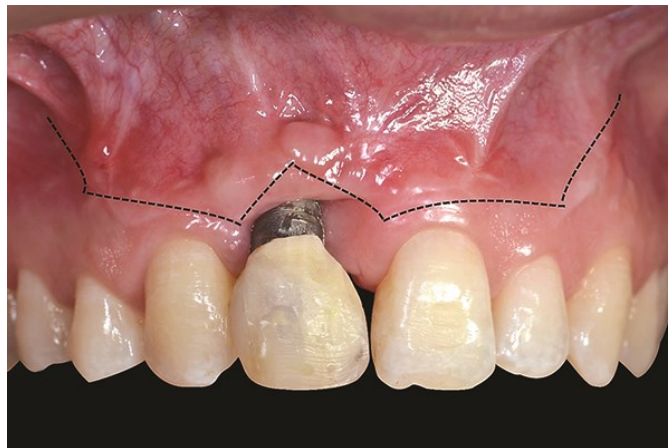The esthetics of a dental implant prosthesis depends on the health and stability of the peri-implant mucosa. Understanding of soft tissue healing and maintenance around dental implants is paramount for implant success.





## **GINGIVAL SHRINKAGE AROUND DENTAL IMPLANTS**

During the healing phase following implant placement surgery (stage 1 surgery) or the transmucosal surgery for abutment connection (stage 2 surgery), the soft tissue re-organises itself according to the new environment (namely, surrounding a metallic implant). Noting the histologic observation made by Berglundh (Berglundh, Lindhe et al. 1991) and other investigator groups (regarding the orientation of the collagen fibre groups in the peri-implant gingival tissue) it is easy to appreciate why the peri-implant gingival tissue appears to shrink during the early stage of wound healing. The longitudinal arrangement of the major collagen fibre groups amplifies the process of collagen fibril contraction (as part of collagen maturation) in the vertical direction.



Clinically, this process is observed as marginal gingiva shrinkage. In the anterior aesthetic zone, the amount of gingival shrinkage can be crucial to the success or failure of a case. Therefore when planning such a case, it is important to take into account the position and structural integrity of the labial bone wall which forms the support base for the labial gingiva.

## **OSSEOINTEGRATION:**

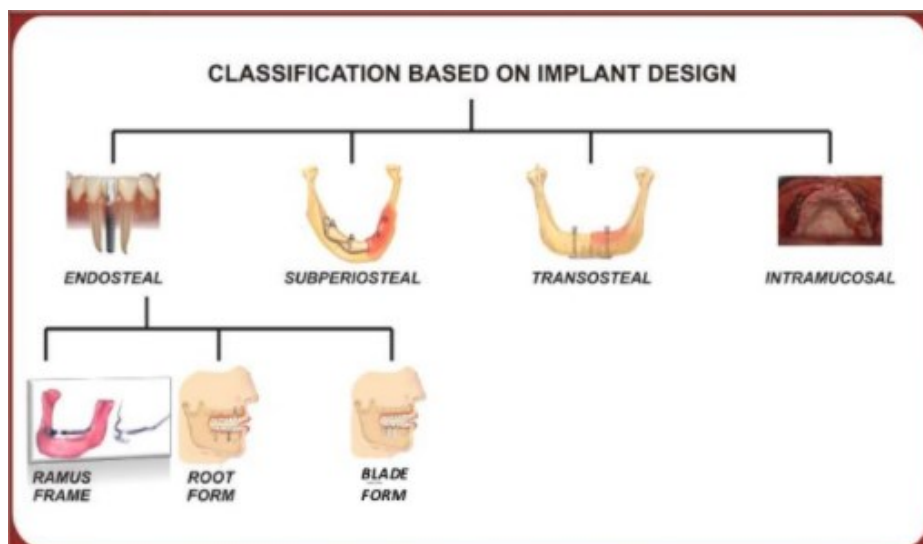
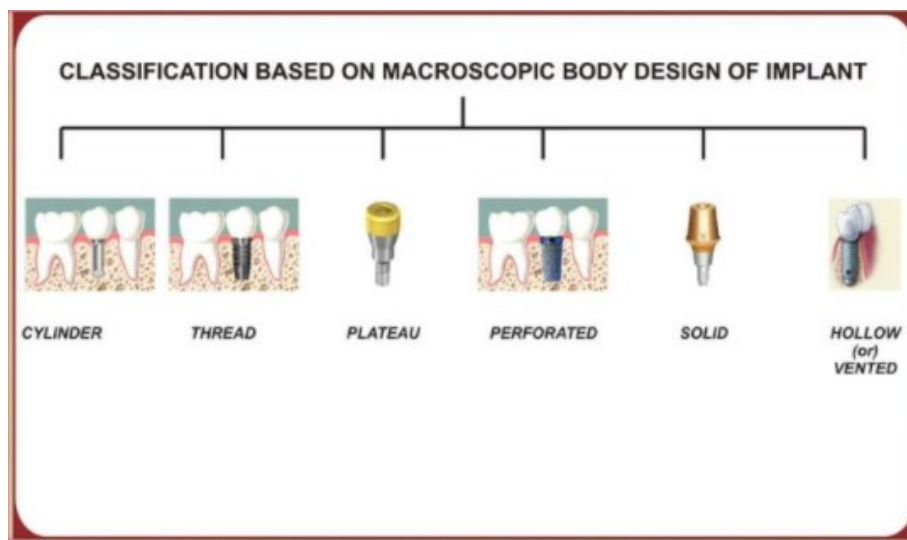
Direct structural and functional connection between ordered living bone and the surface of the load carrying implant.




## DIFFERENT BIOMATERIALS USED FOR IMPLANTS

- Metals & Alloys
- Inert Ceramics
- Calcium phosphate ceramics
- Polymers

## BASIC CLASSIFICATION OF DENTAL IMPLANTS



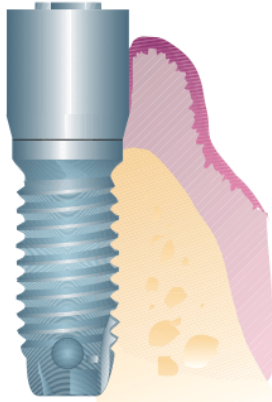


### Contraindications of Implant therapy

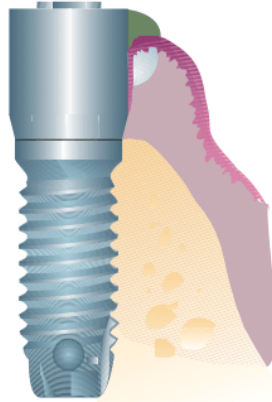
<u><b>ABSOLUTE CONTRAINDICATIONS</b></u>	<u><b>RELATIVE CONTRAINDICATIONS</b></u>
<ol style="list-style-type: none"><li>1. Recent myocardial infarction</li><li>2. Valvular prosthesis</li><li>3. Severe renal disease</li><li>4. Uncontrolled &amp; treatment resistant diabetes</li><li>5. Advanced &amp; untreated osteoporosis</li><li>6. Treatment resistant osteomalacia</li><li>7. Uncontrolled endocrine gland disease</li><li>8. Advanced &amp; uncontrolled acquired immunodeficiency syndrome</li></ol>	<ul style="list-style-type: none"><li>• Systemic hematological disorders</li><li>• Irradiation of the jaw</li><li>• Liver and kidney disorders</li><li>• Osteoporosis/ low bone mineral content</li><li>• Local pathology</li></ul>



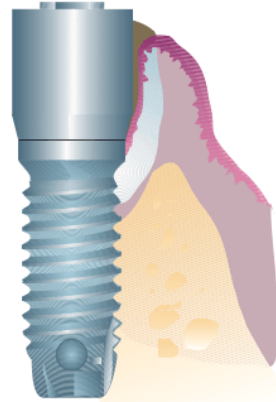
Healthy peri-implant mucosa



Peri-implant mucositis



Peri-implantitis

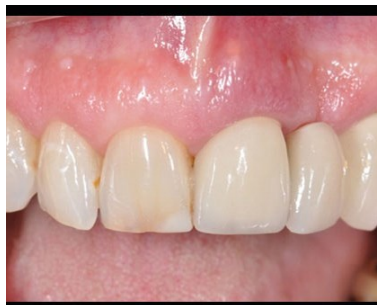

**Peri-implant mucositis:**

Inflammatory changes which are confined to soft tissue surrounding an implant

**Peri-implantitis :**

It is a progressive per-implant bone loss in conjunction with soft tissue inflammatory lesion. It begins at the coronal portion of the implant while the more apical portion of the implant remains osseointegrated.



\*\*\*\*\*

